



Multimodality Imaging in Inflammation: from Morphology to Function and Beyond

Konstantin Nikolaou
Department of Diagnostic and Interventional Radiology

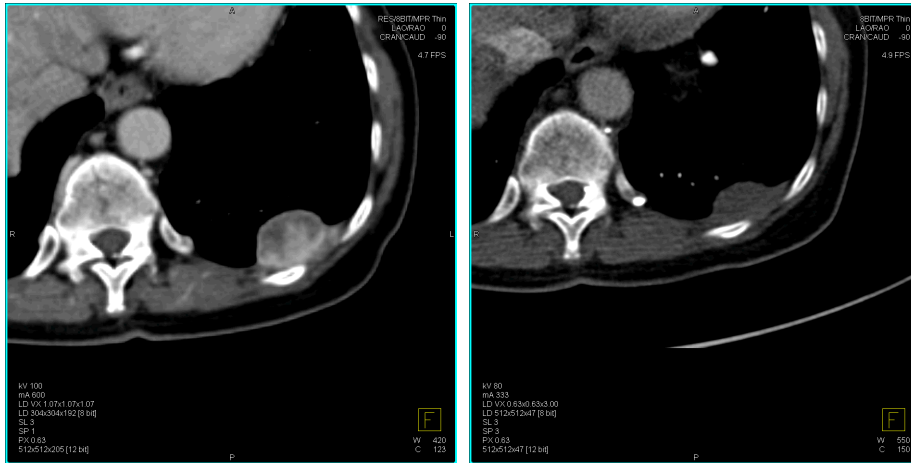


Agenda

- **Oncology**
 - CT Perfusion / Dual Energy CT
 - MR Perfusion (DCE-MRI / ASL)
 - MR-DWI (Diffusion-weighted Imaging)
- **Atherosclerosis and Vasculitis**
 - High-Resolution Coronary CTA
 - CT Perfusion in Vasculitis
 - MRI Carotid: High Resolution and DCE-MRI
- **Myocardium**
 - LGE, Function, Perfusion, Mapping
- **Tissue Characterization: Advanced MR Techniques**
- **Hybrid Imaging**



Advanced CT: Functional Imaging of Tumor Response
RCC, pulmonary met



Pre-Therapy

1 week Sunitinib (Sutent®)

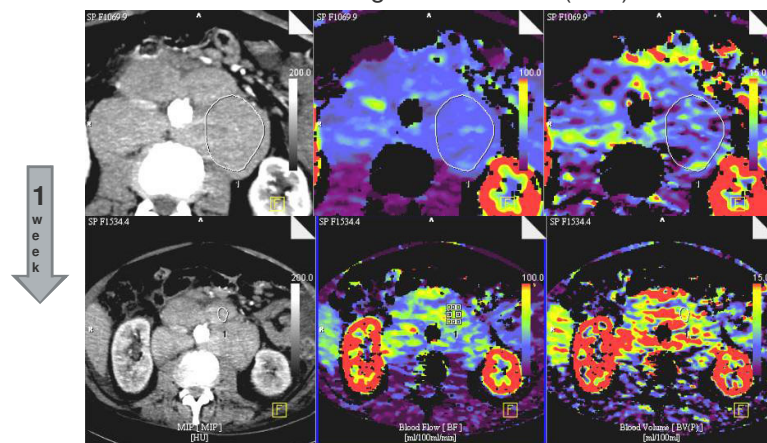
3 |

SFB Inflammation



Advanced CT: Quantitative Perfusion CT Imaging

1 week during anti-CD52 Ab (CLL)



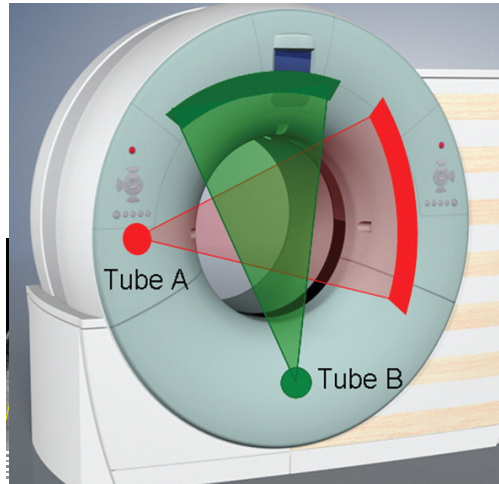
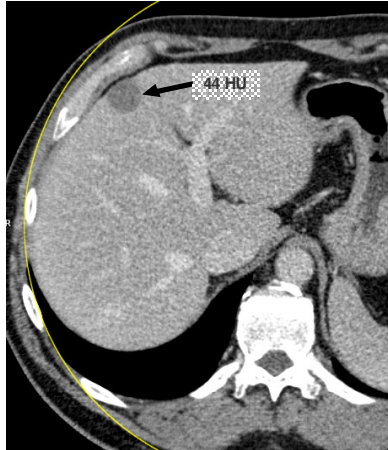
Volume perfusion CT shows marked increase in BF and BV

4 |

SFB Inflammation

Advanced CT: Dual-Energy CT / Spectral CT for Tissue Composition

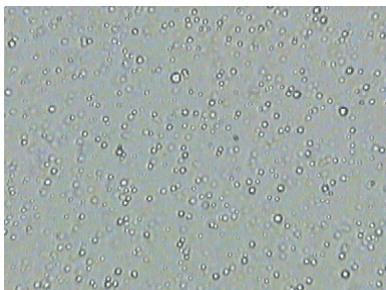
Iodine Content?



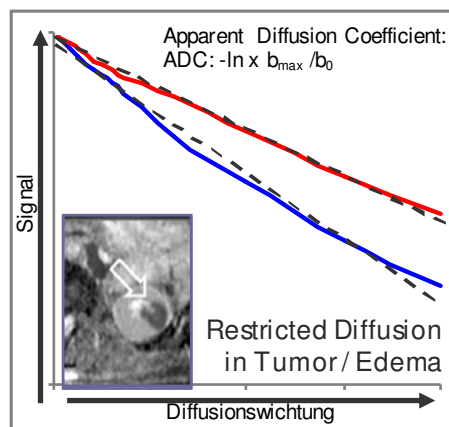
5 |

SFB Inflammation

- No contrast media / Brownian motion
- High cell density restricts diffusion
- Detection/Charactization/Monitoring



<http://www.microscopy-uk.org.uk/dwww/home/hombrown.htm>



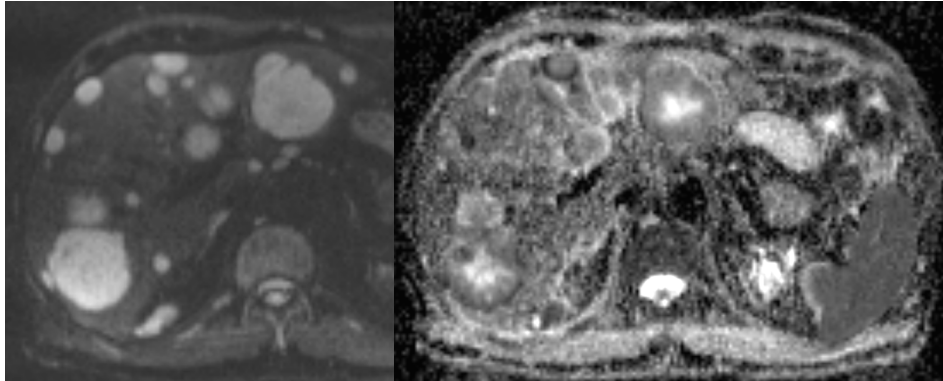
6 |

Subcutanes Colon-CA Xenograft, Regorafenib-Therapie

SFB Inflammation



MR: Functional Diffusion Liver Imaging



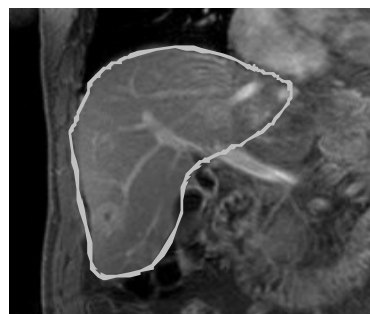
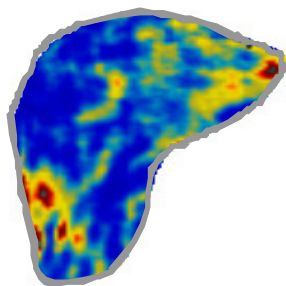
73-year old patient, NET, hepatic metastases, **tumor heterogeneity** visible in ADC-map

7 |

SFB Inflammation



MR: Liver Perfusion (DCE-MRI)



- Signal-time-curves after Gd i.v.
- Kinetic modelling
- of perfusion parameter maps
- Assessment of vascularization and vessel permeability
→ lesion characterization and treatment monitoring

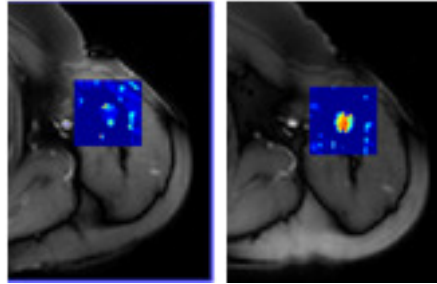
8 |

SFB Inflammation

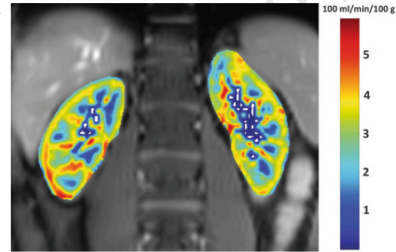


MR: Perfusion Imaging by ASL

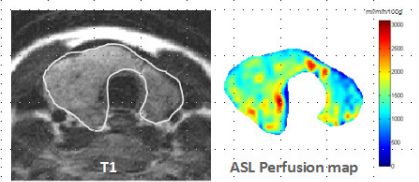
- No contrast media application
- Labeling of blood water protons
- Creation of perfusion maps



NHL- Two weeks after onset of anti-CD20 therapy
ASL: Increased perfusion in responding bone lymphoma



Healthy volunteer, perfusion of medulla and cortex

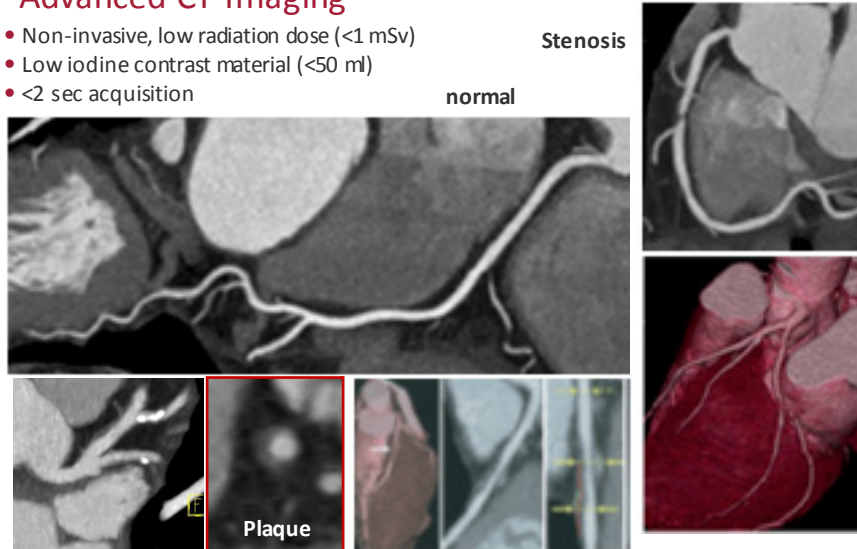


Regional thyroid perfusion assessment in a patient with Graves' disease (M. Basedow)



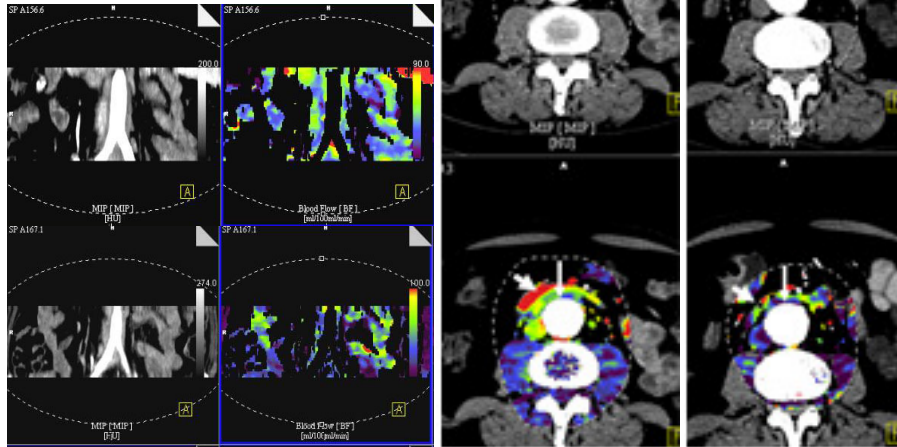
Advanced CT Imaging

- Non-invasive, low radiation dose (<1 mSv)
- Low iodine contrast material (<50 ml)
- <2 sec acquisition



CT Perfusion Imaging

- Morphologic and functional information

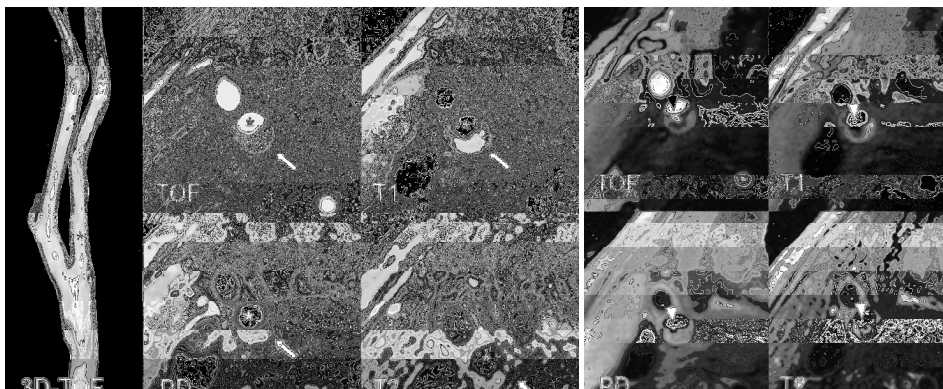


11 |

SFB Inflammation

Advanced MR: Carotid Plaque Characterization

Collaboration with Neuroradiology Prof. U. Ernemann



56 y/o asymptomatic, vulnerable plaque features

Acute plaque rupture

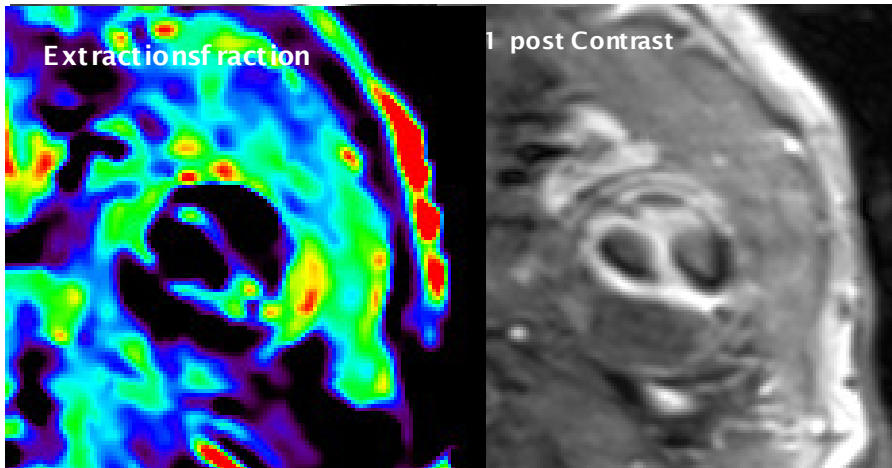
12 |

SFB Inflammation



MR Perfusion for Carotid Plaque Characterization

AHA Typ VI Plaque left CCA



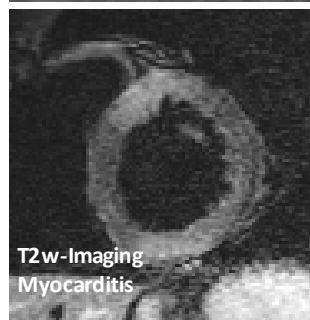
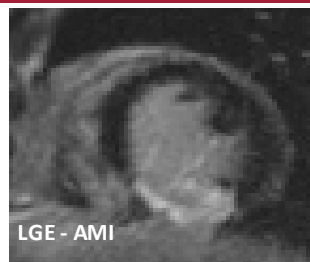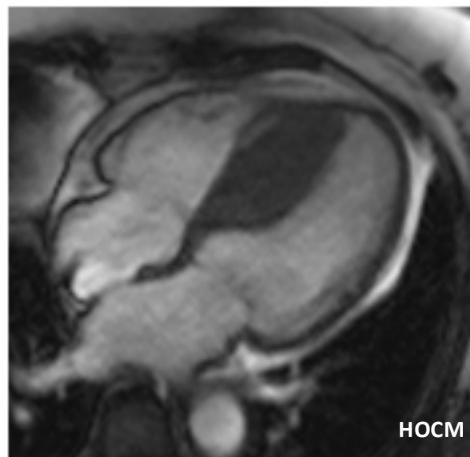
13 |

SFB Inflammation



Advanced MR Cardiac Imaging

- Functional Information
- Enhancement Patterns

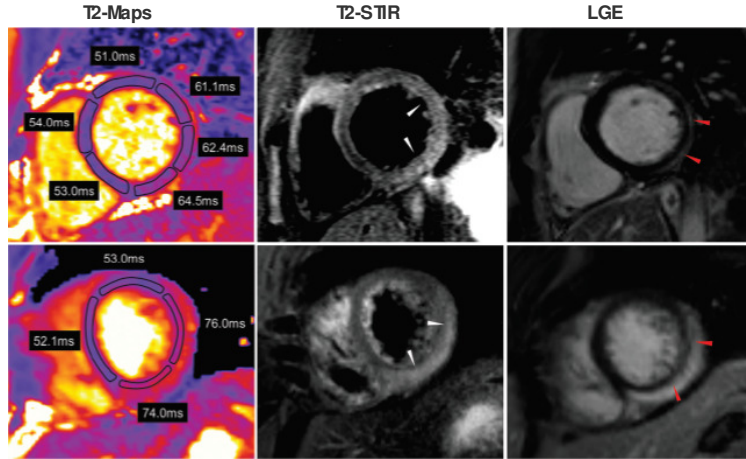


14 |

SFB Inflammation

MR-Mapping: T2 / T1 quantitative relaxation times

- Absolute and relative relaxation times of myocardium
- Detection /Quantification of diffuse inflammatory disease

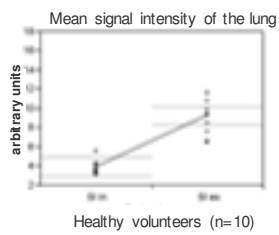


15 |

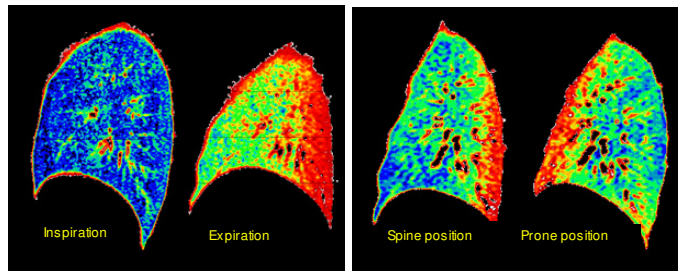
Circ CV Imaging, 2012

SFB Inflammation

MR: Proton Density using very Short TE



- Potential for Allergic / Inflammatory Lung Disease
- Anterior-posterior PD gradient position dependent
- Differences between maximum in- and expiration

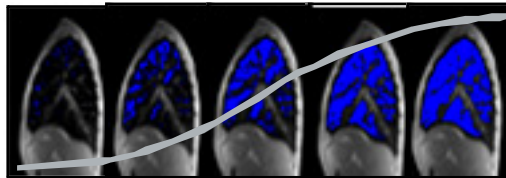
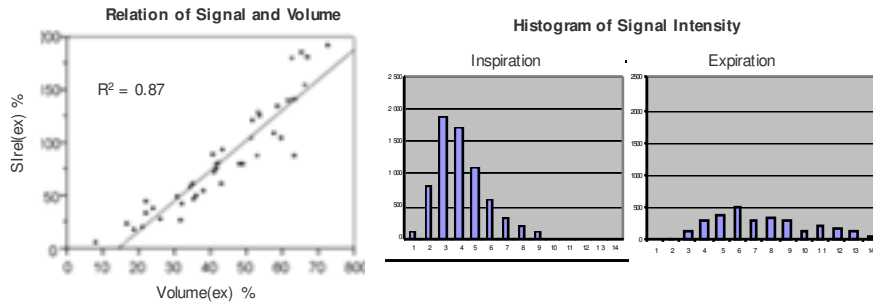


16 |

Hatabu et al. European journal of radiology 1999;29:245-252.

SFB Inflammation

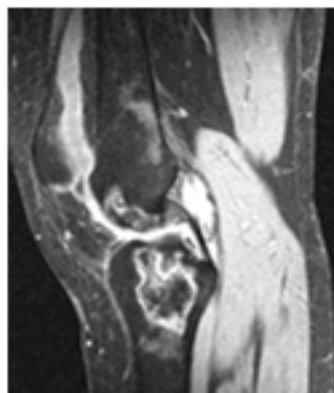
MR: Bronchial inflammation/obstruction: Quantification of Air Trapping



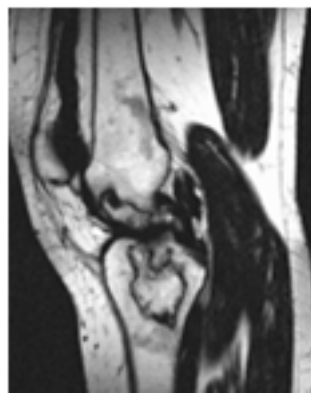
- Segmentation of lung volume
- Stepwise calculation of the relative signal(ex) and cumulative lung volume

**MR: Chemical-Shift-selective Imaging:
Synovitis, Effusion, Osteonecrosis**

Water-selective



Fat-selective

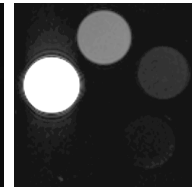

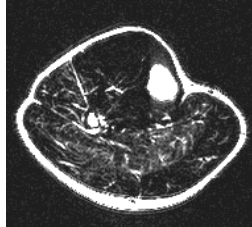
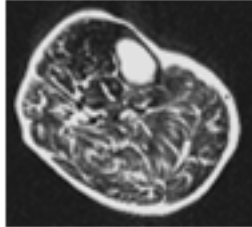




Fat-selective Imaging of Muscle Tissue

Male, 34 y/o

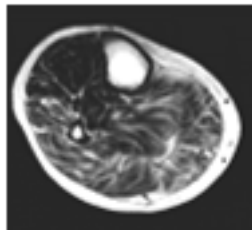
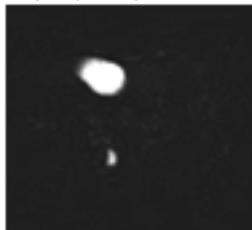
Male, exercises 34 y/o



Lipody strophic Patient

Kennedy

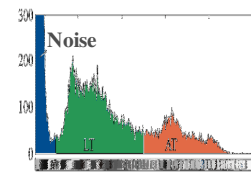
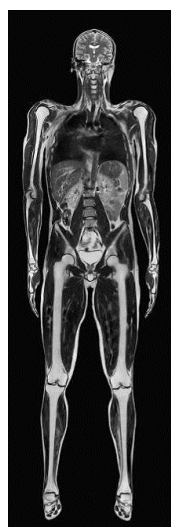Rho-weighted Fat-selective



Quantitative fat-selective
Imaging of muscle in
different degenerative and
inflammatory muscular
disease entities/ **rheumatic**
diseases

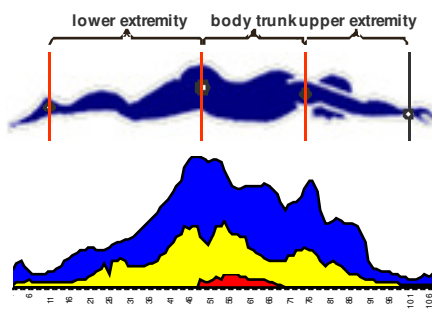


Diabetes and Pre diabetes: Volumetry of Visceral and Subcutaneous Fat



After:

- Compensating Coil characteristics
- Definition of thresholds
- Differentiation of SAT and VAT using „active contours“



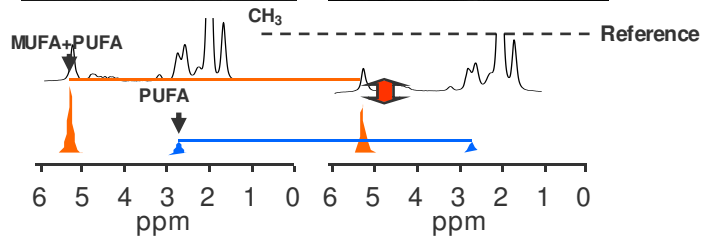
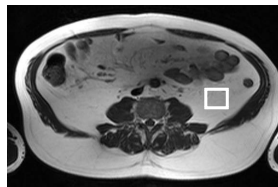
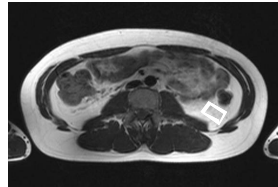
■ Total Cross-Section
■ Adipose Tissue
■ Visceral Adipose Tissue



Composition of Visceral Fat: MR Spectroscopy

small VAT volume

high VAT volume



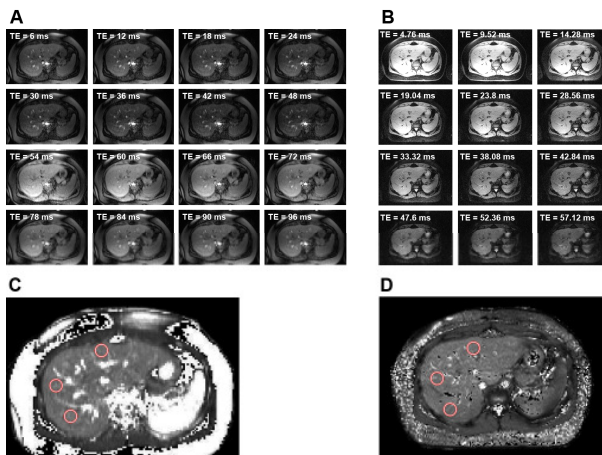
21 |

Machann J et al., NMR Biomed. 2013

SFB Inflammation



Liver inflammation in Non-alcoholic steatosis hepatitis: T2- and T2*-Mapping



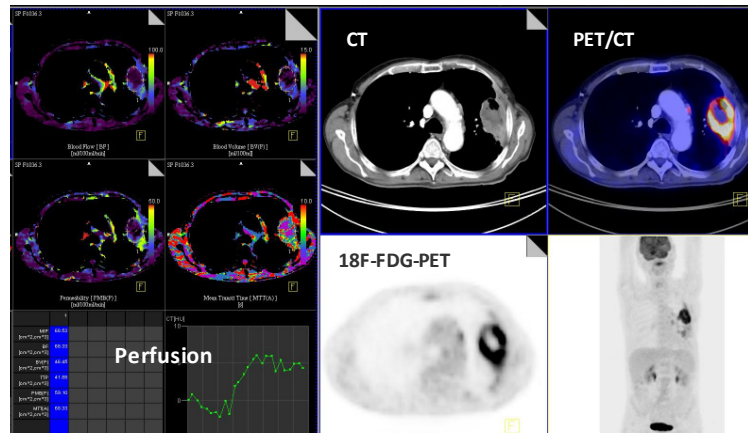
22 |

Bongers, Schick, Machann et al, submitted for publication

SFB Inflammation



PET/CT: Oncology

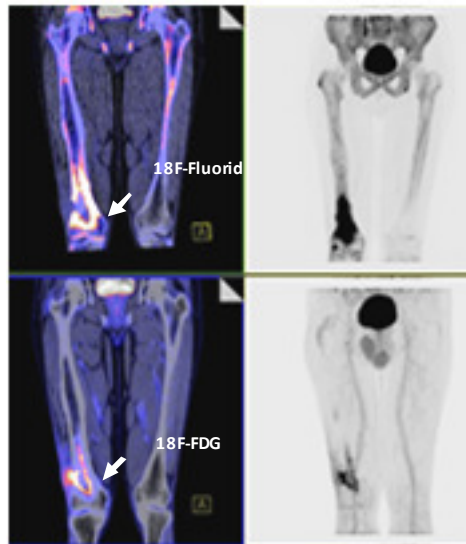


Potential: Evaluation of tumor **metabolism** (PET) and **vascularity** (CT-Perfusion) enables imaging of vascular-metabolic relationships in tumors



PET/CT: Bone Inflammation

- Evaluation of disease activity and accurate assessment of the extent of infection for surgical planning
- Double tracer PET examination:
18F-FDG: Inflammation
18F-Fluorid: bone metabolism
- Complementary information regarding bone infections
- **High resolution CT** provides exact anatomical and structural information of the bone
- Osteomyelitis versus Osteonecrosis after **radiotherapy**

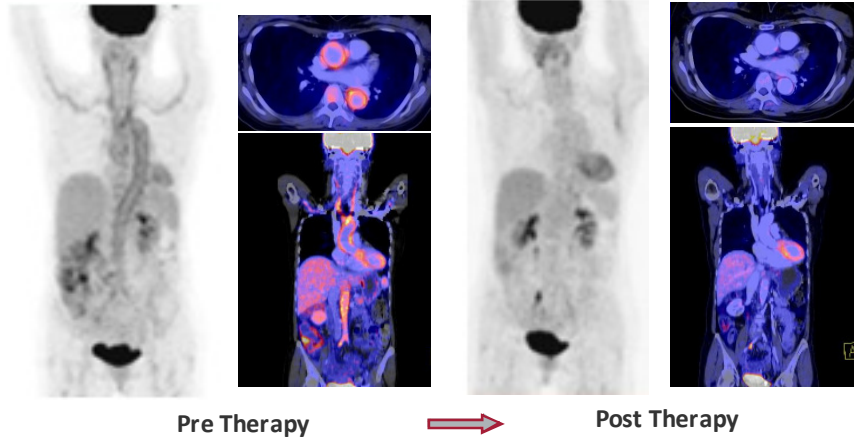


Chronic Osteomyelitis



PET/CT: Vascular Inflammation

Large vessel vasculitis: 18F-FDG-PET/CT



25 |

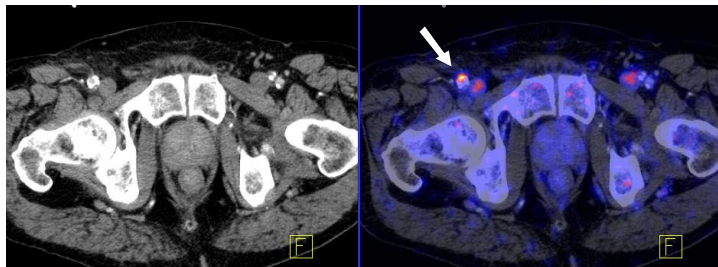
SFB Inflammation



PET/CT: Plaque Imaging

Novel Tracer: 64Cu-GP VI-Fc (= Glykoprotein VI)

- GPVI-Fc binds with high affinity to collagen and atherosclerotic plaque tissue.
- Non-invasive imaging studies (preclinical) with radiolabeled sGPVI-Fc show specific binding activity to vascular lesions in vivo.



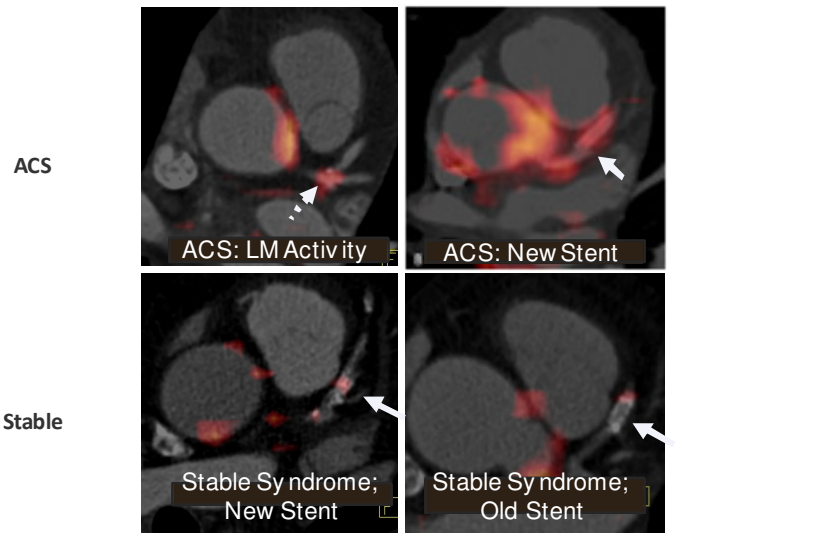
79 y male patient with a significant CAD, 1 week after cardiac catheterization , PET/CT with 64Cu-GPVI-Fc PET/CT, (uptake time 24h), focal tracer uptake at the access site of the right AFC

26 |

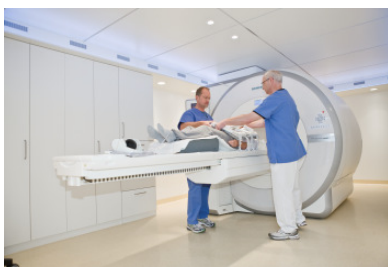SFB Inflammation



PET/CT: Plaque Characterization

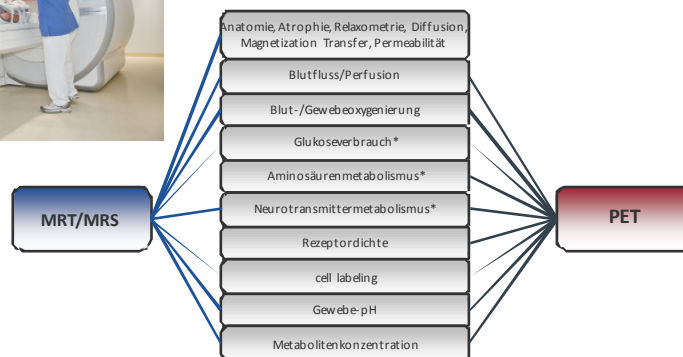


MR/PET



Biograph mMR Fa. Siemens

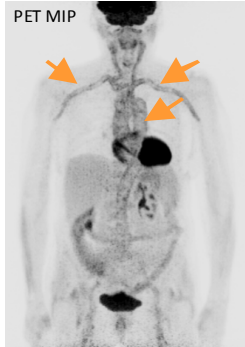Simultaneous acquisition of metabolic (PET) and functional/anatomical (MRI) Parameters:



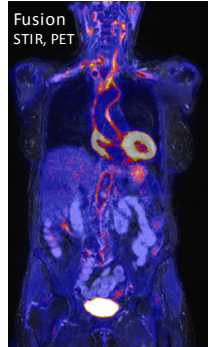
* MRS = Konzentration, PET = Umsatz

MR/PET: Vessel Wall

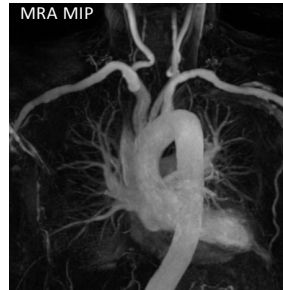Takayasu Vasculitis



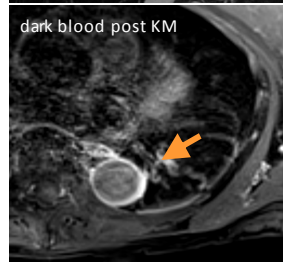
FDG-PET 307 MBq, 122 min p.i.



Initial Stage



No Stenosis



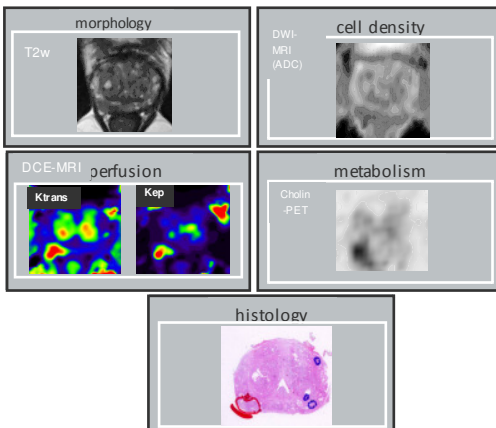
Wall enhancement

76 y/o female, fatigue and muscle score, weakness upper extremity; BSG: 69 mm; CRP: 9,23 mg/dl

MR/PET: Oncology

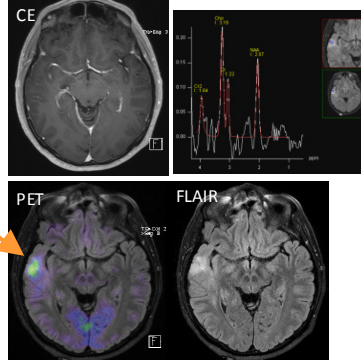
Multi-parametric Tissue Characterization

Prostate Cancer



Glioma *Oligoastrozytom WHO II*

1H-Spektroskopie

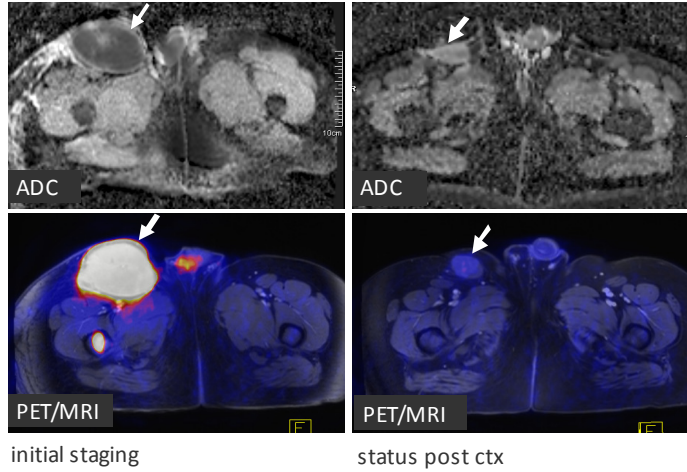


Collaboration with Neuroradiology
Prof. U. Ernemann



MR/PET

16 y/o male w/ lymphoma: Reduction in size, increase in ADC, reduction in SUV → response



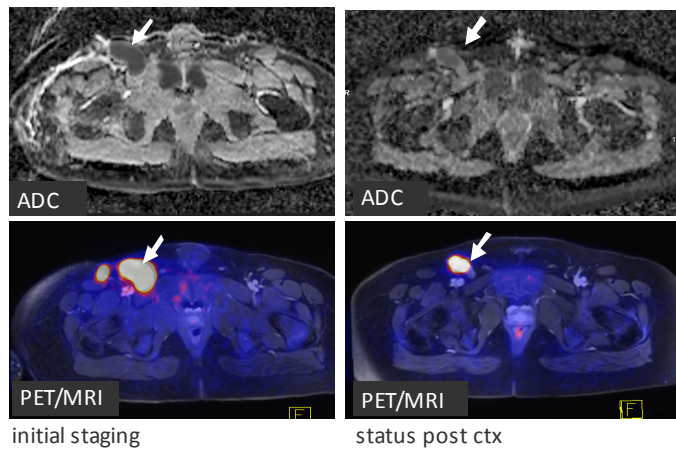
31 |

SFB Inflammation



MR/PET:

Reduction in size, only slight reduction in ADC, persistent SUV
→ suspicion of residual vital tumor



32 |

SFB Inflammation



Thank you!

Fabian Bamberg
Stephan Clasen
Brigitte Gückel
Marius Horger
Mike Notohamiprodjo
Christina Pfannenberger
Jürgen Schäfer
Fritz Schick
Christina Schraml
Nina Schwenzer
Friederike Wolf-Oberhollenzer