

RESEARCH ARTICLE

A brain atlas of the carrion crow (*Corvus corone*)

Ylva Kersten | Bettina Friedrich-Müller | Andreas Nieder

 Animal Physiology Unit, Institute of
Neurobiology, University of Tübingen,
Tübingen, Germany

Correspondence

 Andreas Nieder, Animal Physiology Unit,
Institute of Neurobiology, Auf der
Morgenstelle 28, University of Tübingen,
72076 Tübingen, Germany.
Email: andreas.nieder@uni-tuebingen.de

Abstract

Corvidae, passerine songbirds such as jays, crows, and ravens known as corvids, have become model systems for the study of avian cognition. The superior cognitive capabilities of corvids mainly emerge from a disproportionately large telencephalon found in these species. However, a systematic mapping of the neuroanatomy of the corvid brain, and the telencephalon in particular, is lacking so far. Here, we present a brain atlas of the carrion crow, *Corvus corone*, with special emphasis on the telencephalic pallium. We applied four staining techniques to brain slices (Nissl, myelin, combination of Nissl and myelin, and tyrosine hydroxylase targeting catecholaminergic neurons). This allowed us to identify brain nuclei throughout the brain and delineate the known pallial subdivisions termed hyperpallium, entopallium, mesopallium, nidopallium, arcopallium, and hippocampal complex. The extent of these subdivisions and brain nuclei are described according to stereotaxic coordinates. In addition, 3D depictions of pallial regions were reconstructed from these slices. While the overall organization of the carrion crow's brain matches other songbird brains, the relative proportions and expansions of associative pallial areas differ considerably in agreement with enhanced cognitive skills found in corvids. The presented global organization of the crow brain in stereotaxic coordinates will help to guide future neurobiological studies in corvids.

Abbreviations: A, arcopallium; AA, anterior arcopallium; AD, dorsal arcopallium; AI, intermediate arcopallium; AL, ansa lenticularis; AM, medial arcopallium; AMD, medial dorsal arcopallium; AMV, medial ventral arcopallium; AP, anterior-posterior; APC, caudal part of the posterior arcopallium; APH, parahippocampal area; Av, avalanche; B, nucleus basorostralis pallii; BC, brachium conjunctivum; BCD, brachium conjunctivum descendens; BST, nucleus striae terminalis; CA, commissura anterior; CbL, nucleus cerebellaris lateralis; CbM, nucleus cerebellaris intermedius; CDL, dorsolateral corticoid area; CDLco, core of the dorsolateral corticoid area; CF, crescent field; CI, intermediate corticoid area; CO, chiasma opticum; CP, commissura posterior; CS, nucleus centralis superior; CT, commissura tectalis; CTz, corpus trapezoideum; DA, dorsal arcopallial tract; DLA, nucleus dorsolateralis anterior thalami; DLL, nucleus dorsolateralis anterior, pars lateralis; DLM, medial part of the dorsolateral nucleus of the anterior thalamus; DLP, nucleus dorsolateralis posterior thalami; DM, dorsomedial part of the intercollicular nucleus; DVR, dorsal ventricular ridge; E, ectopallium; FA, tractus fronto arcopallialis; FLM, fasciculus longitudinalis medialis; FPL, fasciculus prosencephala lateralis; FRM, formatio reticularis mesencephalic pars medialis; GCT, substantia grisea centralis; GLv, nucleus geniculatus lateralis pars ventralis; GP, globus pallidus; H, hyperpallium; HA, hyperpallium apicale; HCl, lateral hippocampus; HCm, medial hippocampus; HD, hyperpallium densocellulare; Hp, hippocampal complex; HL, nucleus habenularis lateralis; HM, nucleus habenularis medialis; ICo, Nucleus intercollicularis; Imc, Nucleus isthmi pars magnocellularis; lpc, nucleus isthmi pars parvocellularis; LAD, lamina arcopallialis dorsalis; LHy, hypothalamus pars lateralis; IMAN, Lateral part of MAN; LMD, lamina mesopallium dorsalis; LMV, lamina mesopallialisventralis; LoC, locus ceruleus; LPS, lamina pallialis subpallialis; MAN, magnocellular nucleus of the anterior nidopallium; MD, dorsal mesopallium; MLd, nucleus mesencephalicus lateralis; MVtr, nucleus motorius nervi trigemini; MV, ventral mesopallium; N, nidopallium; NA, nucleus angularis; NC, caudal nidopallium; NCL, caudolateral nidopallium; NCLd, dorsal caudolateral nidopallium; NCLm, medial caudolateral nidopallium; NCLv, ventral caudolateral nidopallium; NCM, caudomedial nidopallium; Nif, nucleus interfascialis; nIV, nucleus nervi trochlearis; NL, nucleus laminaris; NM, nucleus magnocellularis; OM, occipito-mesencephalic tract; Ov, nucleus ovoidalis; PaM, nucleus paramedianus; PBS, phosphate buffered saline; PFA, paraformaldehyde; PFC, prefrontal cortex; PL, Nucleus pontis lateralis; PM, nucleus pontis medialis; Pt, pretectal Nucleus; PVM, nucleus periventricularis magnocellularis; QF, tractus quintofrontalis; RA, robust nucleus of the arcopallium; RP, nucleus reticularis pontis caudalis; Rpc, nucleus reticularis parvocellularis; RPg, nucleus reticularis pontis caudalis pars gigantocellularis; Rt, nucleus rotundus; Ru, nucleus ruber; S, septum; SAC, stratum album centrale; SLu, nucleus semilunaris; SNC, substantia nigra pars compacta; SpL, nucleus spiriformis lateralis; SpM, nucleus spiriformis medialis; Str, striatum; TeO, tectum opticum; TFM, tractus thalamo frontalis et frontalis-thalamicus medialis; TH, tyrosine hydroxylase; TnA, nucleus teania amygdalae; TrO, tractus opticus; TSM, tractus septopallio-mesencephalicus; TT, tractus tectothalamicus; TTD, nucleus tractus descendens trigemini; TV, nucleus tegmenti ventralis; Vc, caudal trigeminal nucleus; VeD, nucleus vestibularis descendens; VeL, nucleus vestibularis lateralis; VeM, nucleus vestibularis medialis; VS, nucleus vestibularis superior; VTA, ventral tegmental area; X, area X; ZEBra, Zebra finch Expression Brain Atlas.

This is an open access article under the terms of the [Creative Commons Attribution-NonCommercial-NoDerivs](https://creativecommons.org/licenses/by-nc-nd/4.0/) License, which permits use and distribution in any medium, provided the original work is properly cited, the use is non-commercial and no modifications or adaptations are made.

© 2022 The Authors. *The Journal of Comparative Neurology* published by Wiley Periodicals LLC.

1 | INTRODUCTION

Corvidae, or corvids, is a widely distributed family of passerine birds comprising species such as crows, ravens, jackdaws, or jays (Ericson et al., 2005). As oscine passerines or songbirds, corvids possess a full set of song nuclei (Izawa & Watanabe, 2007; Kersten et al., 2021; Wang et al., 2009) and show flexible vocal capabilities (Bluff et al., 2010; Brecht et al., 2019; Enggist-Dueblin & Pfister, 2002). Beyond a flair for vocal flexibility, corvids are also known for remarkable cognitive abilities (Clayton & Emery, 2005; Güntürkün & Bugnyar, 2016). They prospectively solve problems (Dally et al., 2006; Rinnert & Nieder, 2021; Veit & Nieder, 2013), manufacture and use tools (Weir et al., 2002), estimate set size (Ditz & Nieder, 2015, 2016a, 2020; Kirschhock et al., 2021), store and manipulate information in memory (Boeckle & Bugnyar, 2012; Rinnert et al., 2019), and exhibit aspects of sensory consciousness (Nieder et al., 2020). Such cognitive feats are special among the birds and are thought to emerge from the telencephalon of corvids. A volume increase in associative pallial structures and particularly high associative neuron numbers seem to accompany enhanced cognitive skills in corvids (Burish et al., 2004; Iwaniuk & Hurd, 2005; Mehlhorn et al., 2010; Rehkämper et al., 1991; Ströckens et al., 2022). However, with the exception of a few specialized neuroanatomical studies (Izawa & Watanabe, 2007; Kersten et al., 2021; Sen et al., 2019; von Eugen et al., 2020), a detailed brain atlas of the corvid brain is lacking.

In light of hypertrophied pallial association areas in corvids, most notably the nido- and mesopallium, the neuroanatomical maps of other well-studied songbirds are only of limited value to understand the neuroanatomy of the crow pallium. The only telencephalic area that has been studied recently in some anatomical (Sen et al., 2019; von Eugen et al., 2020) and physiological details in corvids (Nieder, 2017) is the nidopallium caudolaterale (NCL). The NCL is located at the top of the sensorimotor loop and receives highly processed information from all sensory modalities (Güntürkün, 2005). Based on anatomical and physiological characteristics in pigeons, the NCL is thought to be the functional avian equivalent to the prefrontal cortex (PFC), which enables cognitive control in mammals (Güntürkün, 2005; Moll & Nieder, 2015; Nieder, 2017).

Here, we present a brain atlas of a typical and widely distributed corvid species, the carrion crow, *Corvus corone*. With this, we complement previous atlases established for other birds (chick: Kuenzel & Masson, 1988; Puelles et al., 2007; Van Tienhoven & Juhasz, 1962; pigeon: Karten & Hodos, 1967; zebra finch: Nixdorf-Bergweiler & Bischof, 2007; Karten et al., 2013; canary: Stokes et al., 1974) by a corvid songbird species. The carrion crow, or Eurasian crow, *C. corone* L., is one of the most common bird species and is widely distributed in the Palearctic (biogeographic realm that includes Europe, parts of North Africa, and most of Asia; Kryukov et al., 2012). With a body weight of around 500 g and a wingspan of roughly 100 cm, it is the smaller cousin of the raven (*C. corax*). The taxonomic status of *C. corone* remains controversial (De Knijff, 2014). However, *C. corone* is most commonly regarded as a single species—a convention we follow. *Corvus corone* occurs most prominently as the all-black subspecies *C. corone corone* and the black and gray subspecies *C. c. cornix*, also called “hooded crow.”

Many authorities consider them geographical races of one species (Haring et al., 2012; Wolf et al., 2010), whereas other authors treat them as separate species (Parkin et al., 2003). Despite their marked phenotypic differentiation, there is an apparent lack of genetic differentiation (Poelstra et al., 2014). In fact, the two species occasionally crossbreed to have fertile offspring, and the genomes of *C. c. corone* in Germany are much more similar to those of *C. c. cornix* than to those of *C. c. corone* in Spain (Poelstra et al., 2014). From a brain organization point of view, we think it is safe to treat *C. c. cornix* and *C. c. corone*, and possibly other *C. corone* subspecies (Kryukov et al., 2012), as one and the same species. As a rather typical and widespread crow species, the brain organization of *C. corone* can be representative of other species of the corvid family.

2 | METHODS

For this study, seven adult carrion crows (five males, two females; age range: 2.5–7 years) obtained from the institutes' facility were used. Body weight ranged between 430 and 474 g, while brain weight ranged from 7.1 to 7.9 g. The rostrocaudal dimension of the crow's brain ranged between 27.1 and 28.1 mm.

The crows were anesthetized by a mixture of ketamine and xylazine (50-mg ketamine, 5-mg/kg xylazine), and the head was placed in a commercially available stereotactic holder (David Kopf Instruments, Fuzjunga, CA 91042, USA; Model 1430 Stereotaxic Frame; with ear bar locator position—anterior–posterior [A/P] zero) and ear bars for pigeons (Model # 856 Ear Bars; 20° tapered tip to a 4.8-mm shoulder with a 3-mm diameter by 2-mm long protrusion). A simple beak biting rod was added so that the beak would be held at a 45° angle below the horizontal axis. The beak bar was a simple steel bar (2-mm diameter) that was slid through the holes of two parallel standing fixing rails (on either side of the crow's head), which were attached at a 45° angle at the ear bars. The position of the ear bars relative to the brain marked the AP 0.0-mm coordinate.

An incision was made along the midline of the head, and the first bone layer of the skull was carefully removed to localize the midsagittal sinus. We applied marks to the crow's brain to allow for stereotactic mapping and to calculate the shrinkage of the tissue that occurred during histological processing. Marks were set by inserting a fine cannula in the dorsoventral direction. Using the caudal bifurcation of the midsagittal sinus as a reference, two marks were placed 10 mm lateral to the bifurcation and 10 mm anterior to the bifurcation in both hemispheres. In addition, two marks were placed 10 mm lateral and 10 mm anterior to this reference. Subsequently, crows were injected with a lethal dosage of sodium pentobarbital (Narcoren, 50 mg/kg) and perfused with 0.12 M phosphate-buffered saline (PBS) including heparin, followed by 4% paraformaldehyde (PFA) in 0.12 M phosphate buffer (PB). All procedures were carried out according to the guidelines for animal experimentation and approved by the responsible national authorities, Regierungspräsidium Tübingen, Germany.

The brain was removed from the skull and postfixed in 4% PFA overnight. Afterwards, the brain was sunk in an uprising sucrose solution, ending in 30% sucrose solution. Four sets of 30 μ m

(sagittal) to 40 μm (coronal) thick slices were cut using a cryostat (Leica Biosystems, 35576 Wetzlar, Germany; CM1900). Slices were mounted on SuperFrost™ Ultra Plus object plates (Thermo Fisher) or collected free-floating in 0.1% sodium azide in 0.12 M PB.

Four staining protocols were applied to alternating sections (Kersten et al., 2021). For the first series of every brain, a Nissl stain (0.1% cresyl violet) was applied; the second series was stained for myelin (using 0.2% gold chloride solution; Schmued, 1990), while the third series was stained for both Nissl and myelin by combining the staining protocols. In the fourth series, antibody staining against tyrosine hydroxylase was performed. Tyrosine hydroxylase is a rate-limiting enzyme for catecholamine synthesis (Smeets & Reiner, 1994) and can be used to find dopaminergic cells in the vertebrate brain since dopamine is a catecholamine (Holtz, 1939).

Tissue sections were rinsed in 0.12 M Phosphate Buffer Saline (PBS) and incubated in 0.3% hydrogen peroxidase (H_2O_2) in 0.2% Triton X-100 in PBS to quench endogenous peroxidases. After rinsing, sections were blocked in 5% normal goat serum (NGS, Linaris, 69221 Dossenheim, Germany; S-1000) and bovine serum albumin (Vector Laboratories, Newark, CA 94560, USA; SP-5050) in 0.2% Triton X-100 in PBS and incubated with the primary antibody (mouse anti-tyrosine hydroxylase (TH) antibody, ImmunoStar, Hudson, WI 54016-0488, USA; Cat# 22941, RRID:AB_572268, 1:1000) in 0.5% Triton X-100 in PBS for 72 h with gentle movement at 4°C. Sections that were used for negative controls were incubated in 0.5% Triton X-100 in PBS and 2.5% NGS. All sections were rinsed in PBS and incubated in the secondary antibody (biotinylated antimouse IgG (H + L) produced in goat, Sigma, 82024 Taufkirchen, Germany; SAB3701068, RRID:AB_2910246, 1:1000) for 2 h. Afterwards, slices were rinsed, incubated for an hour in a complex of avidin and biotin (Elite ABC Kit, Peroxidase [Standard], PK-6100, Vector Laboratories, according to factory recommendation) and rinsed in PBS again. Sections were developed in 3-3'-diaminobenzidine (DAB) and nickel amplified (DAB Peroxidase Substrate Kit, SK-4100, Linaris, according to factory recommendation). Afterward, slices were rinsed in PBS and mounted on SuperFrost™ Ultra Plus object plates, dehydrated and coverslipped in Entellan mounting medium (Merck KGaA, 64203 Darmstadt, Germany).

The stained tissue sections were then imaged using an AxioScan Z.1 scanning microscope (Carl Zeiss Microscopy GmbH, 37081 Göttingen, Germany) with a Plan-Apochromat 20x/0.8 objective. None of the images was z-stacked but represent data from a single focal plane. Brightness and contrast were adjusted to every image. After the scanning process, the images were examined and converted to TIFF files using the Zeiss software ZEN (Zen 2.5 lite, blue edition, Carl Zeiss). Structures and subdomains were compared with neuroanatomical data of other corvid species, such as the jungle crow, *C. macrorhynchos*, or the house crow, *C. splendens* (Izawa & Watanabe, 2007; Sen et al., 2019). However, since not every structure is described in these articles and because the jungle crow atlas has not been updated with the latest findings in crow and songbird literature, we also used the zebra finch atlas and additional zebra finch neuroanatomy studies to

map the carrion crows brain (Lovell et al., 2020; Mello et al., 2019; Montagnese et al., 1996).

Brain drawings were generated with Corel DRAW X7 software. To generate a 3D reconstruction of the carrion crow's brain, we used the manual contour function of the NeuroLucida software (MBF Bioscience). The tracings of each slide were then stacked together and visualized in the 3D visualizer. Moreover, the smoothing function was used to smooth the surface of the stacked images. For every pallial subdomain, snapshots were taken.

3 | RESULTS

We mapped anatomical regions in sagittal and coronal slides throughout the crow brain with special emphasis on the telencephalon and the pallial regions therein. In addition, 3D depictions of pallial regions were reconstructed from these slices. In general, the overall organization of the carrion crow's brain is comparable to other oscines, such as the zebra finch (Karten et al., 2013; Lovell et al., 2020; Figure 1, Figure 2). However, the relative proportions and expansions of pallial areas sometimes differ considerably. In the following description, we, therefore, focus on the neuroanatomy and organization of the different pallial subdomains in the carrion crow. The most efficient staining to define the different pallial subdomains was basic Nissl staining. Laminae that separate the subdivisions, as well as different cell clustering characteristics, were best visible in Nissl stained sections. Therefore, we will focus our investigation of the telencephalic global anatomy mainly on Nissl staining and supplement it with other staining techniques for specific delineation and characterization aspects.

3.1 | Nidopallium

The pallial subdomain that dominates most of the caudal telencephalon is the nidopallium (Figure 3). From posterior to anterior, the nidopallium covers nearly the whole extent of the telencephalon until it ends in the rostral tip around the AP (AP level in mm from the back pole) 20.2 (Figures 1 and 3). Nidopallial cells clustered together in groups between 1 and 6 cells in high-resolution Nissl-stained slides (Figure 4a). The nidopallium borders ventromedially to the arcopallium and the striatum. The lamina arcopallialis dorsalis (LAD) separates the arcopallium from the nidopallium, whereas the lamina pallio subpallius (LPS) delineates the striatum from the nidopallium. Anterior to AP 10, the mesopallium constitutes the dorsolateral border of the nidopallium (Figure 3); the mesopallium is separated from the nidopallium by the lamina mesopallium ventralis. In the 3D reconstruction, it appears as if the nidopallial tissue is molded around neighboring subfields such as the striatum, arcopallium, and the mesopallium (Figures 5a,b and 3). The nidopallium harbors the three song nuclei HVC (acronym used as a proper name), nucleus interfacialis, and magnocellular nucleus (MAN of the anterior nidopallium), as well as the auditory field L (shown in detail in Kersten et al., 2021).

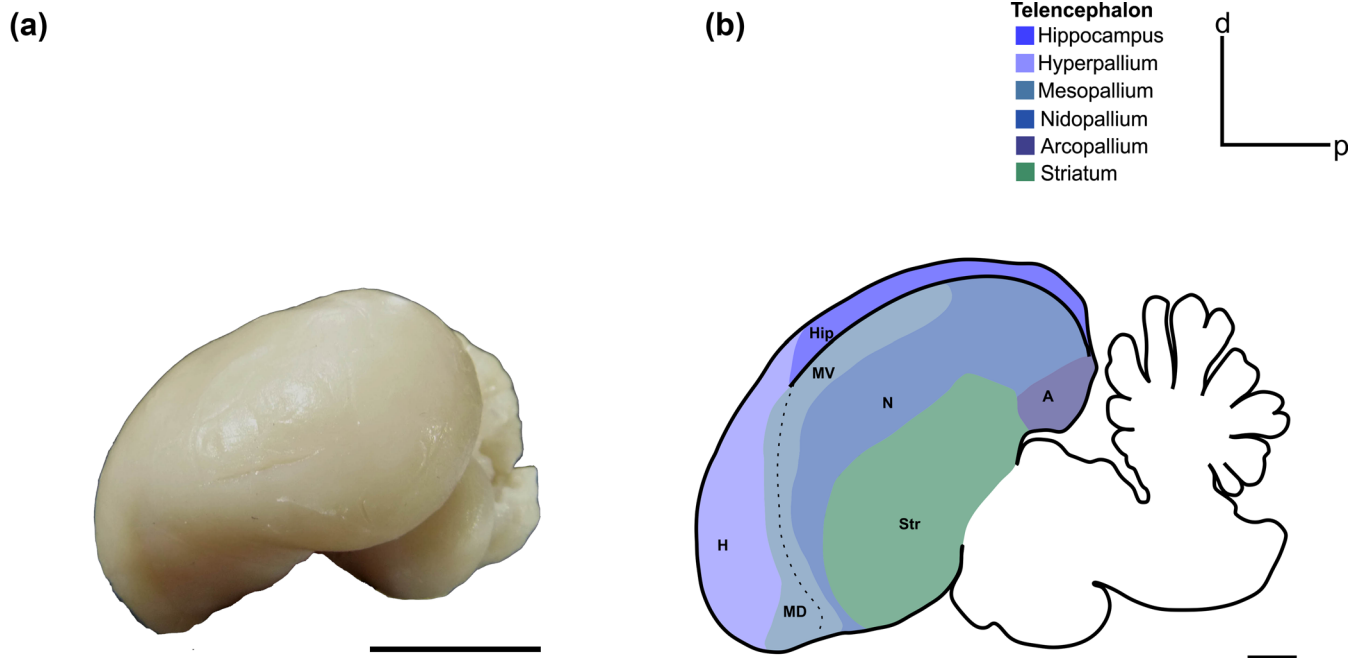


FIGURE 1 Caudolateral view of the carrion crow's brain (a) and schematic drawing of the sagittal view of the carrion crow's brain showing the overall anterior–posterior (AP) expansion of the pallial subdomains (b). Scale bar in (a) = 1 cm, scale bar in (b) = 2000 μm . Abbreviations can be found in the abbreviation list

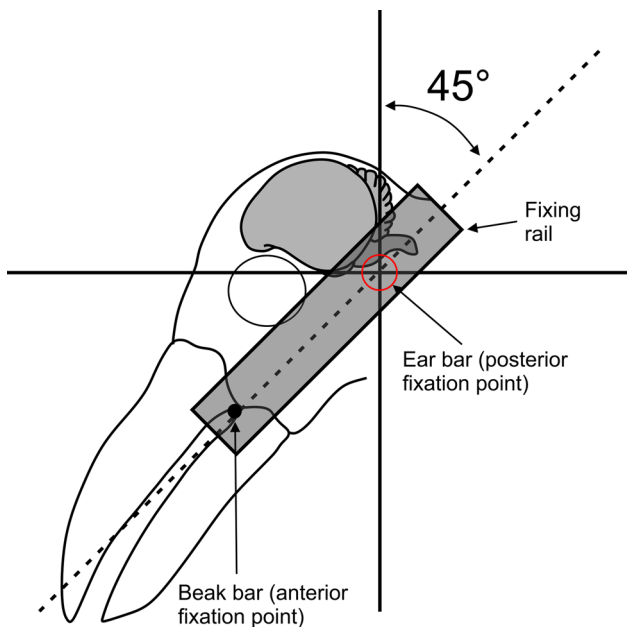


FIGURE 2 Schematic drawing of the stereotactic position used in this study. The head of the crow was held at a 45° angle relative to the ear bars by a beak bar that was attached to two parallel standing fixing rails

A high-level associative subregion of the nidopallium is the NCL. This area is thought to be a functional equivalent of the primate PFC (Güntürkün, 2005; Güntürkün & Bugnyar, 2016; Nieder, 2017). The corvid NCL can be visualized in coronal sections in the crow's brain (Sen et al., 2019; Veit & Nieder, 2013; Veit et al., 2014; von Eugen et al., 2020). Based on slides stained against TH, we were able to delin-

eat several subfields of the NCL and the caudal nidopallium (Figures 3 and 6) that were previously described in carrion crows and zebra finches (von Eugen et al., 2020). The subfields were identified based on the fiber density of TH+ fibers and the presence of so-called “baskets,” which are TH-positive fibers that seem to coil around unstained perikarya (Waldmann & Güntürkün, 1993). Notably, TH+ fibers as well as the baskets show axonal boutons. The density of the TH+ fibers in the NCL regions leads to a darker tissue in overview slides. The overall expansion of the NCL subfields reaches from 1.8 AP until 7.2 AP. The posterior border of the striatum coincides with the fading of the NCL subfields from posterior to anterior, offering an easy locatable landmark.

Among the NCL subfields, the medial NCL (NCLm) and the ventral NCL (NCLv) appear first from posterior to anterior (Figures 3 and 7b,d). The NCLm is the only subfield that can be demarcated throughout the whole expansion of the NCL and can be located dorsal to the arcopallium following the arch of the LAD. NCLm shows darkly stained baskets and a dense fiber mesh (Figure 6a).

NCLv can be demarcated in the lateral part of NC (Figures 3 and 6). In the most caudal levels, NCLv forms a curve from the dorsolateral NC to NCLm and joins it at its most lateral point (Figure 7d). Going rostrally, this connection comes off, and the NCLv covers the most lateral part of the NCL (Figures 3 and 6). NCLv is characterized by a less dense TH+ fiber and basket density compared to the other NCL subregions. Nevertheless, it still shows higher TH+ activity than the surrounding NC tissue (Figure 6a).

The last subfield, the dorsal NCL (NCLd), is located in the middle of the rostrocaudal expansion of the NCL (Figure 6a). It first appears as a small, oval-shaped area in the dorsal NC and throughout its




FIGURE 3 Series of whole (coronal) Nissl-stained sections of the carrion crow's brain with accompanying schematic plates of identified brain nuclei and a color-coded composition of the pallial subdomains in the telencephalon. Closed broken lines indicate fiber tracts, while dotted lines represent the borders of subdomains in the pallial subdivisions. Single straight lines indicate striking fibers that pass between two subdomains. The coordinates indicate the position of the image along the AP-axis. Scale bars = 2000 μm . Abbreviations can be found in the abbreviation list

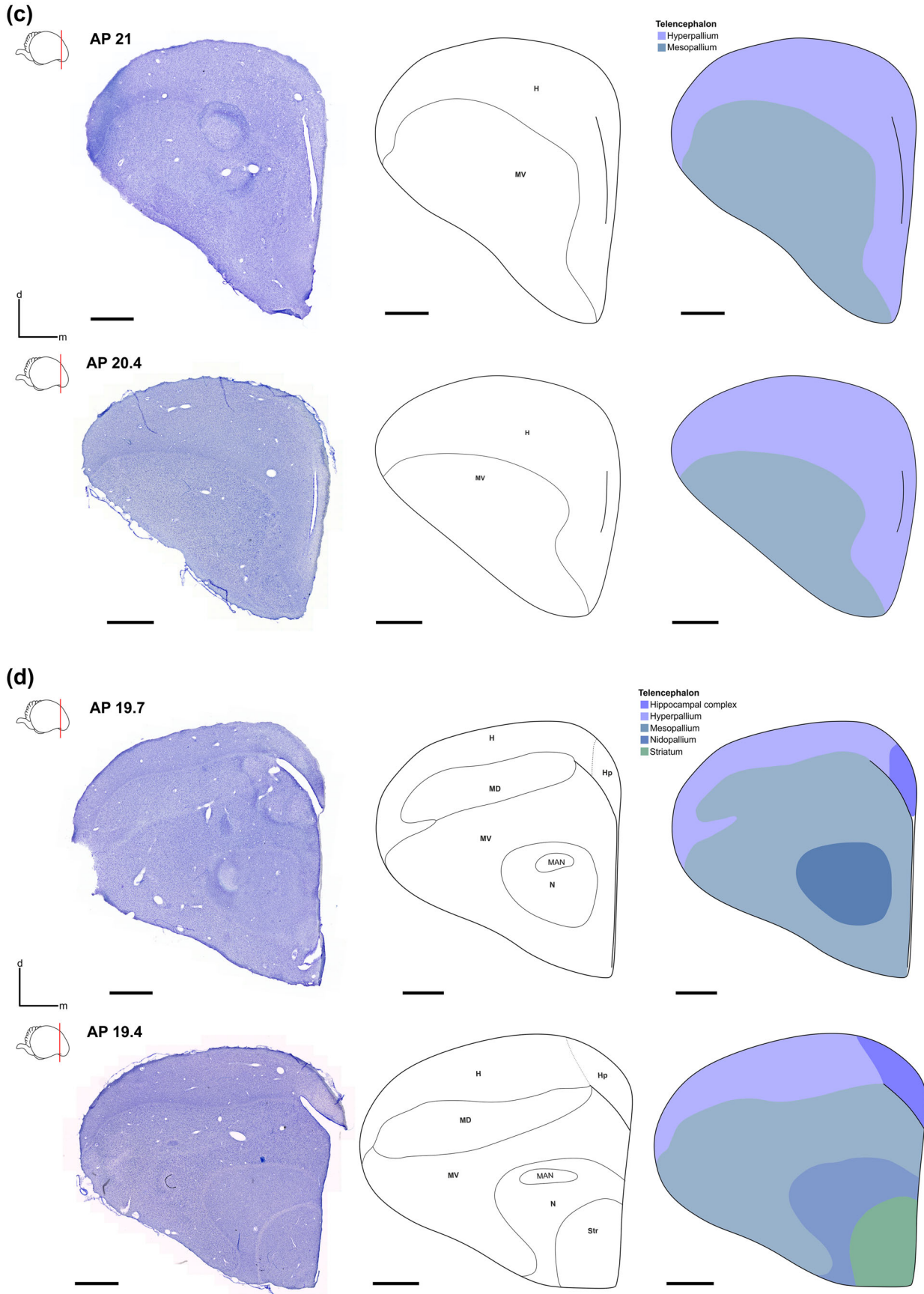


FIGURE 3 Continued

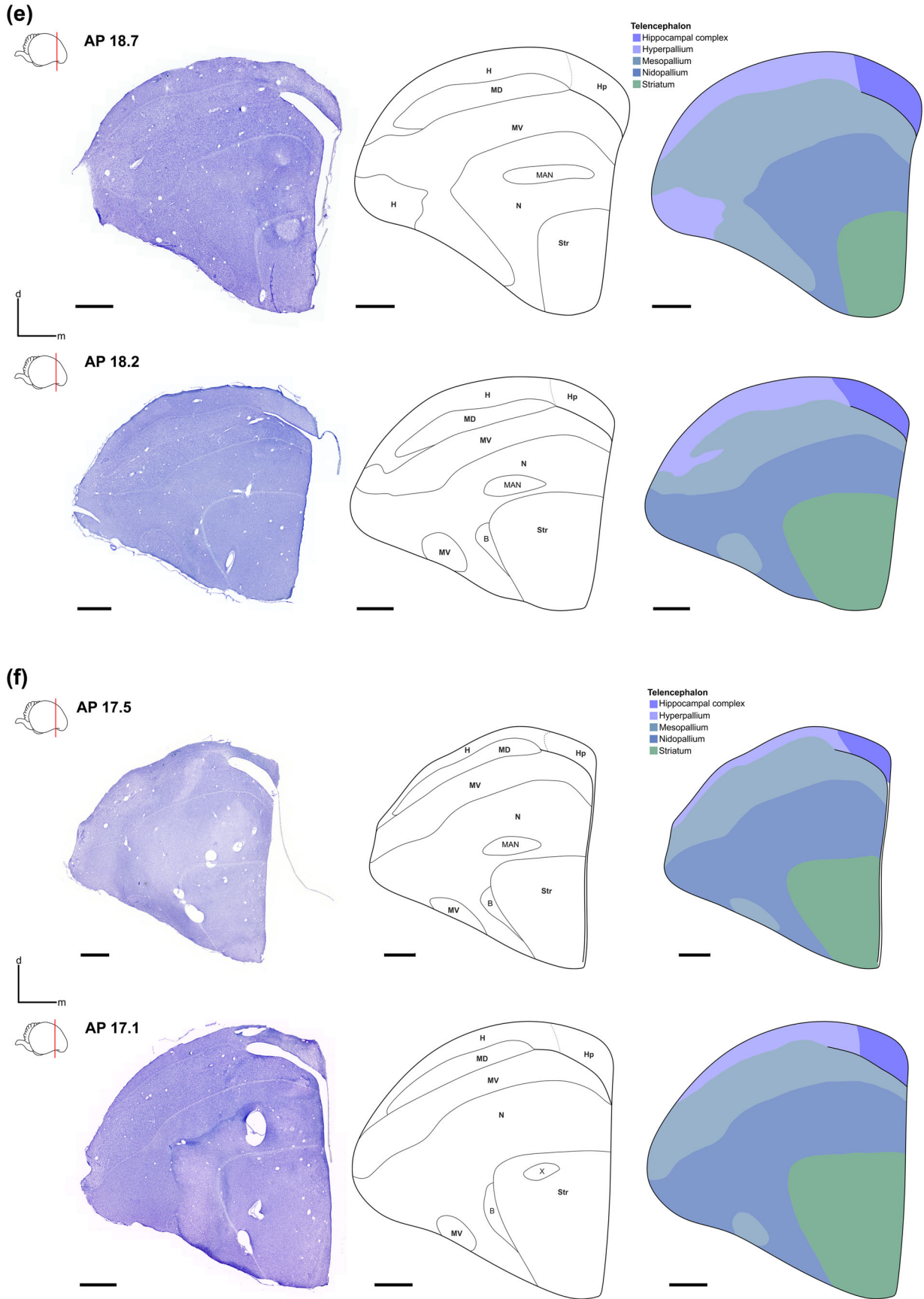


FIGURE 3 Continued

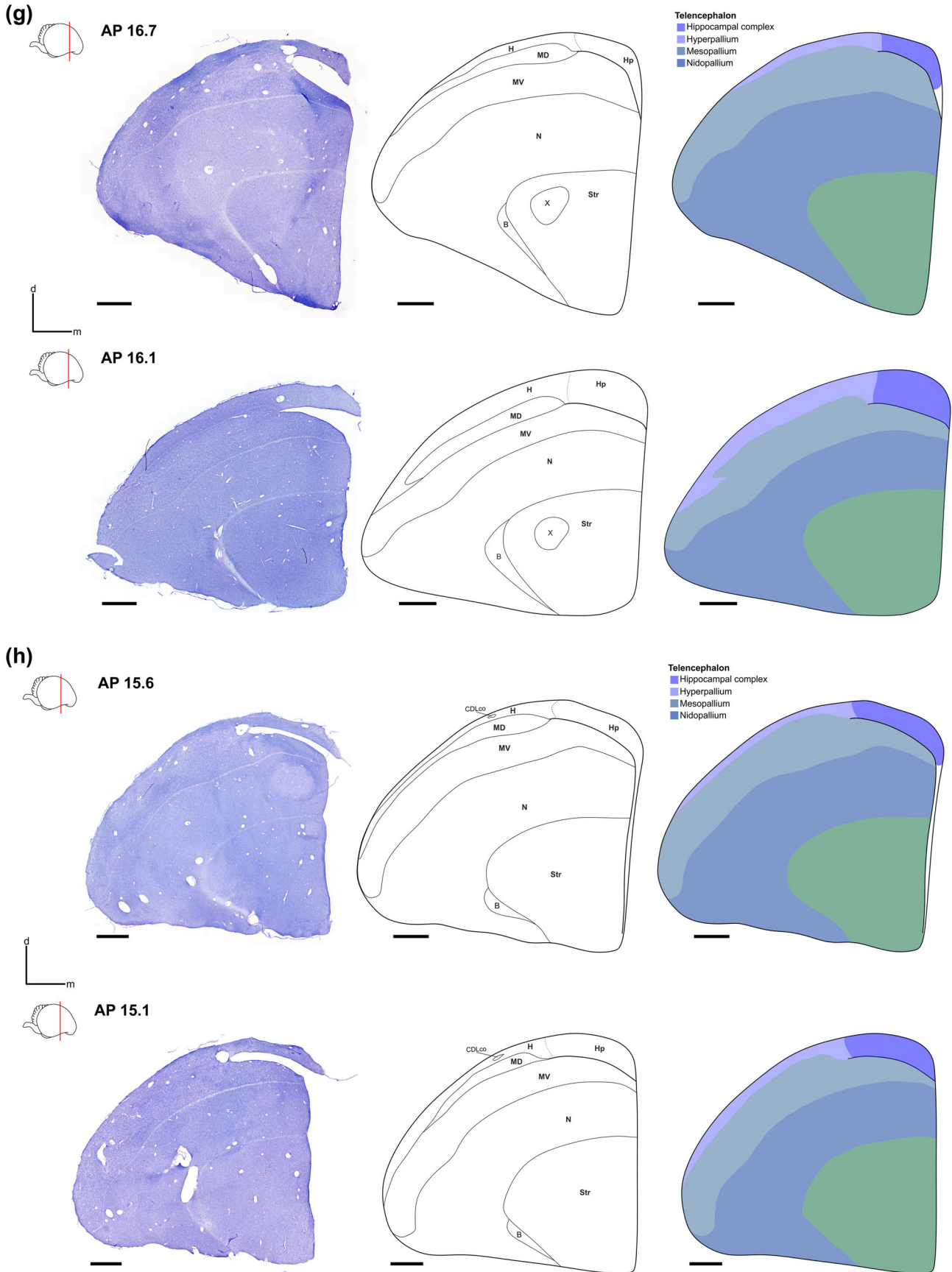


FIGURE 3 Continued

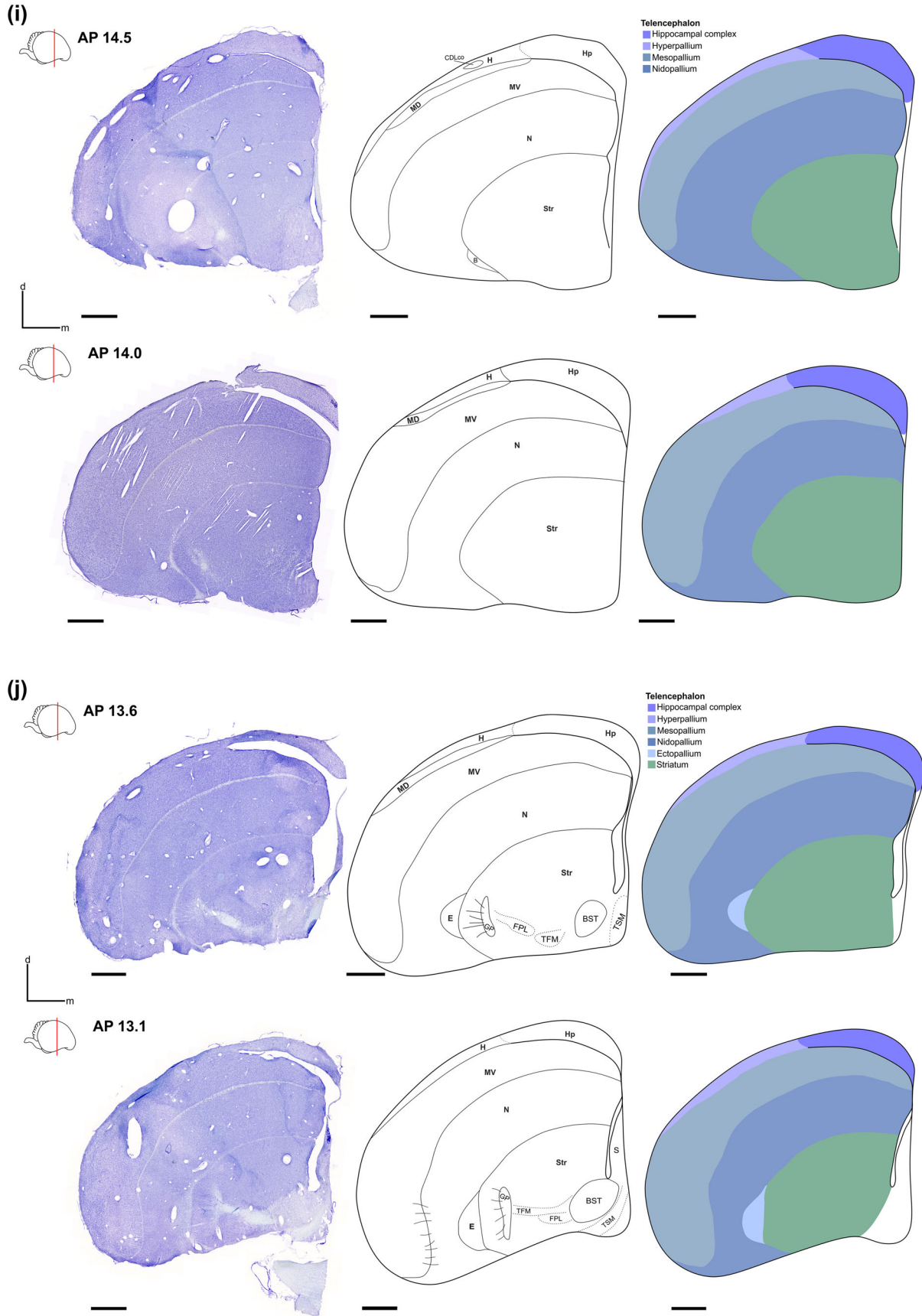
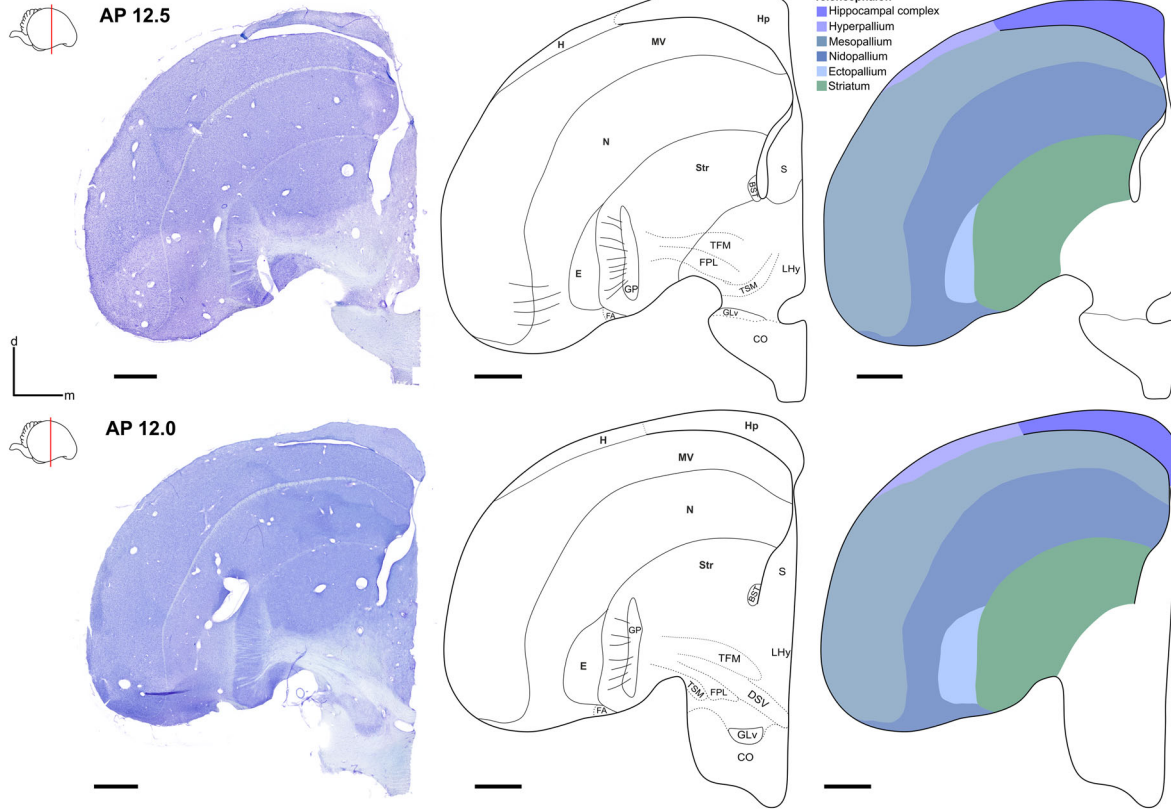


FIGURE 3 Continued

(k)



(l)

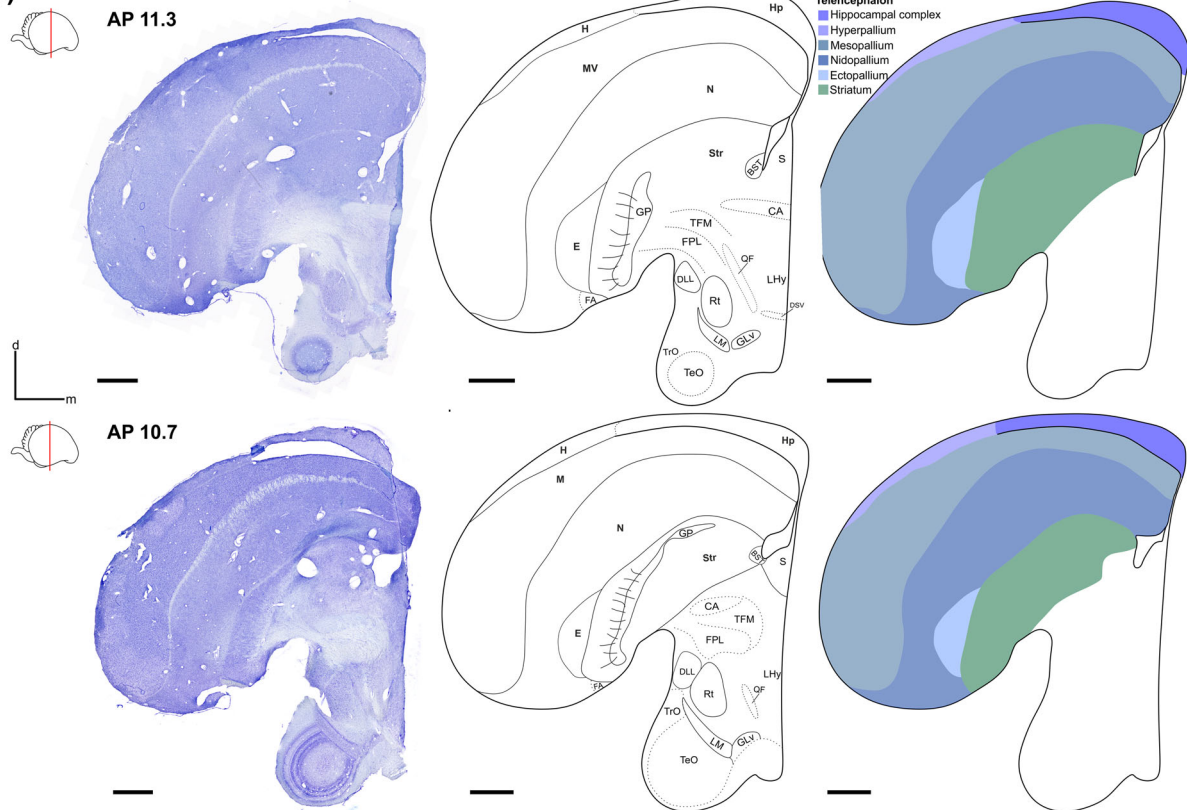


FIGURE 3 Continued

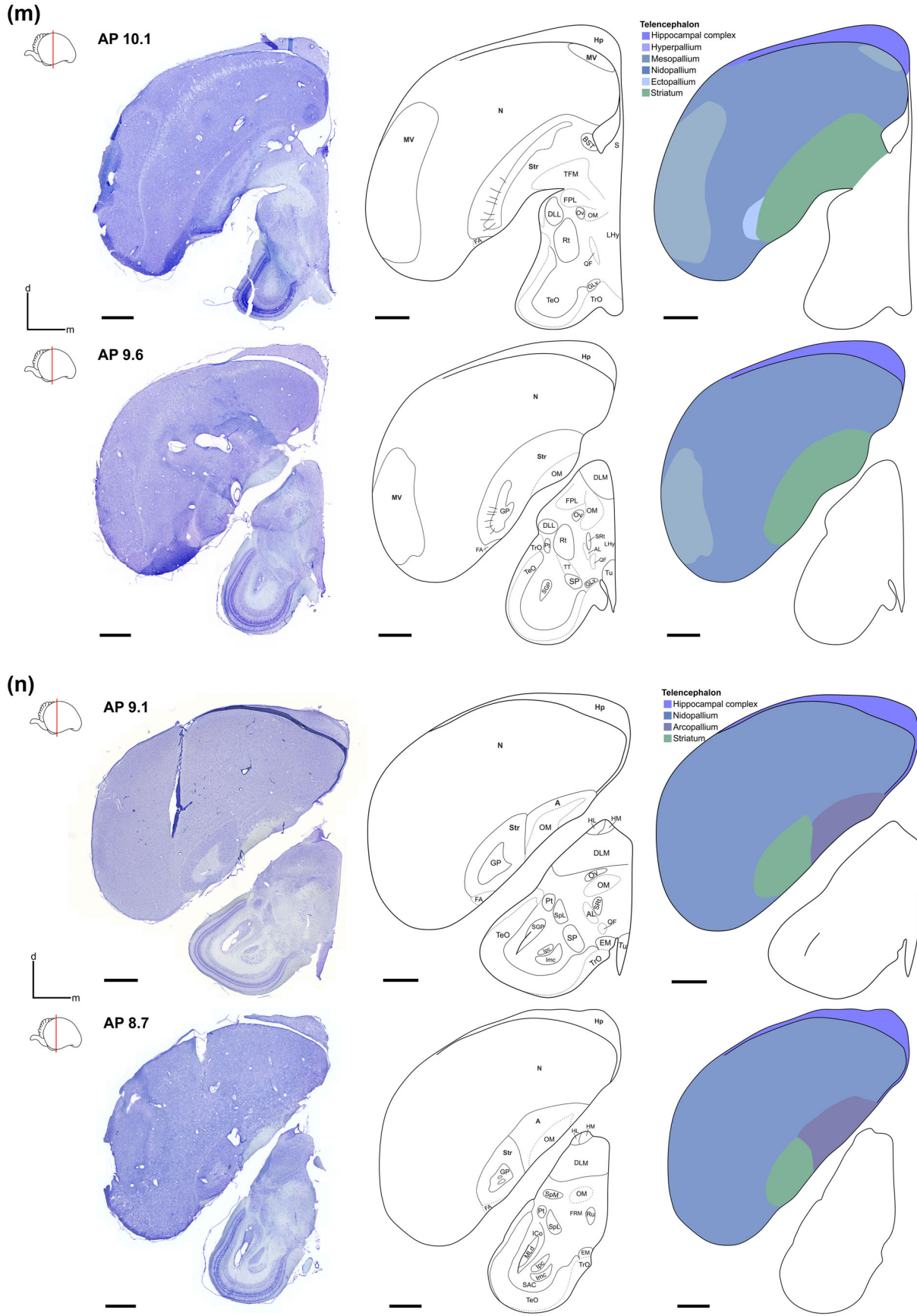


FIGURE 3 Continued

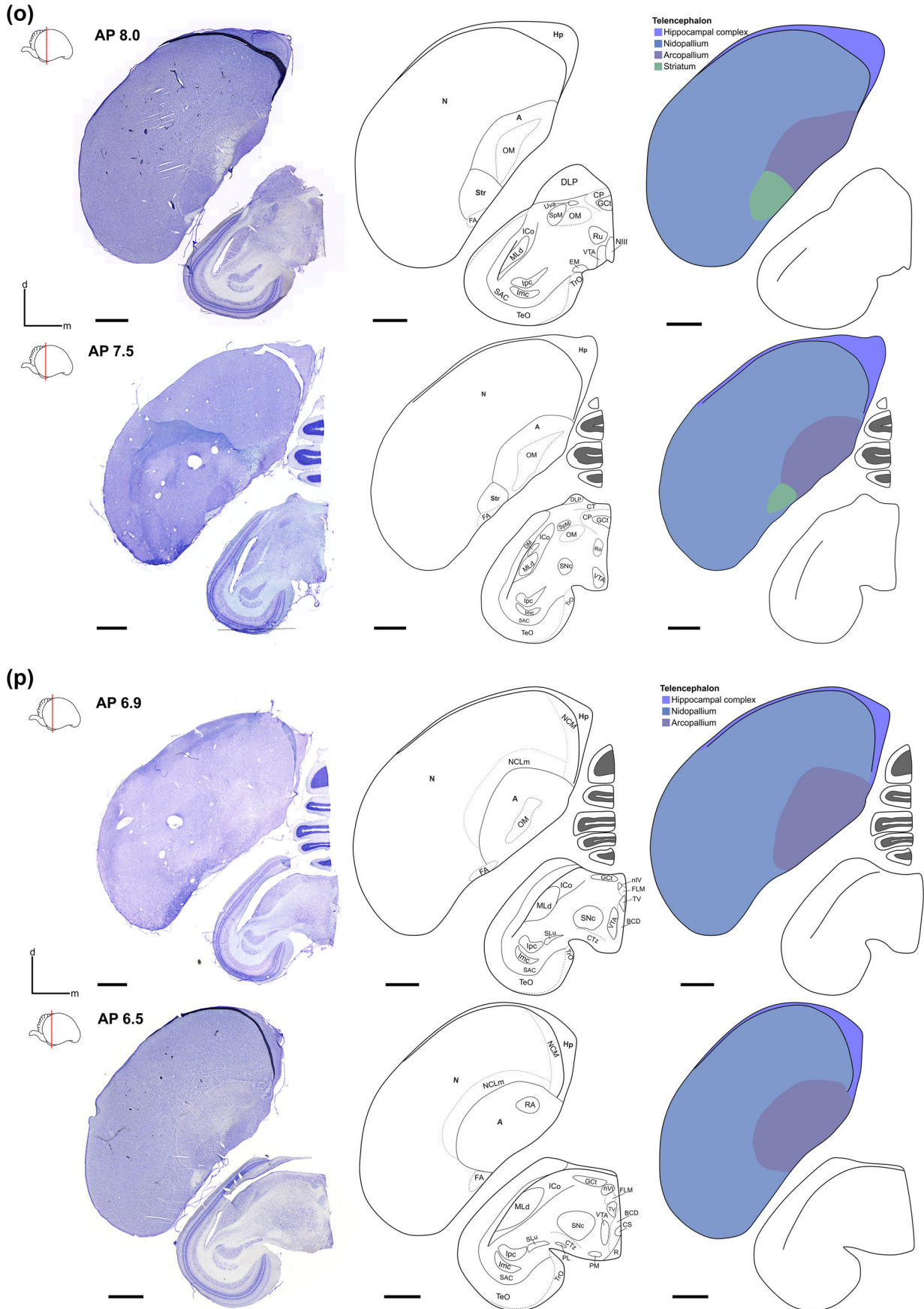


FIGURE 3 Continued

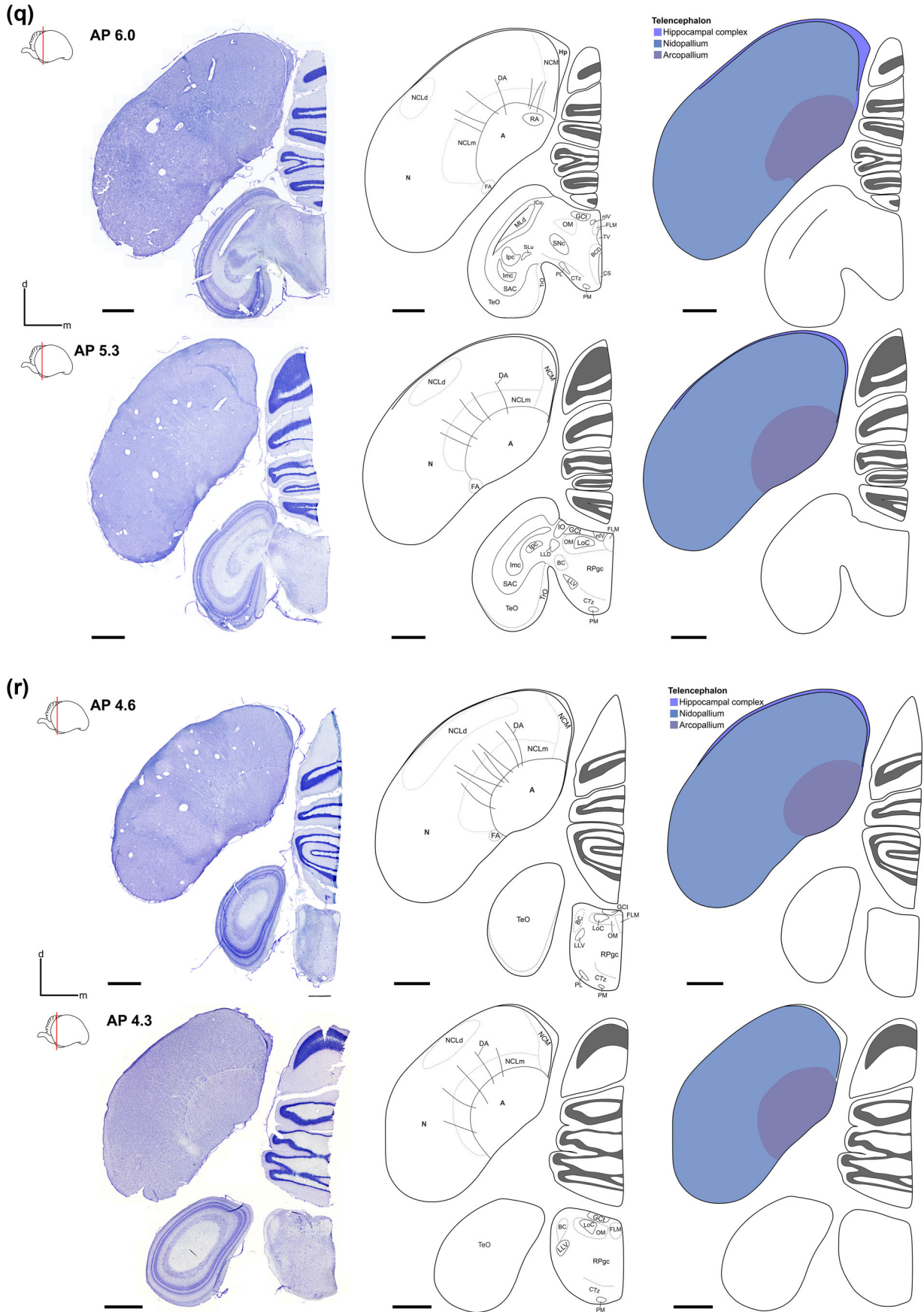


FIGURE 3 Continued

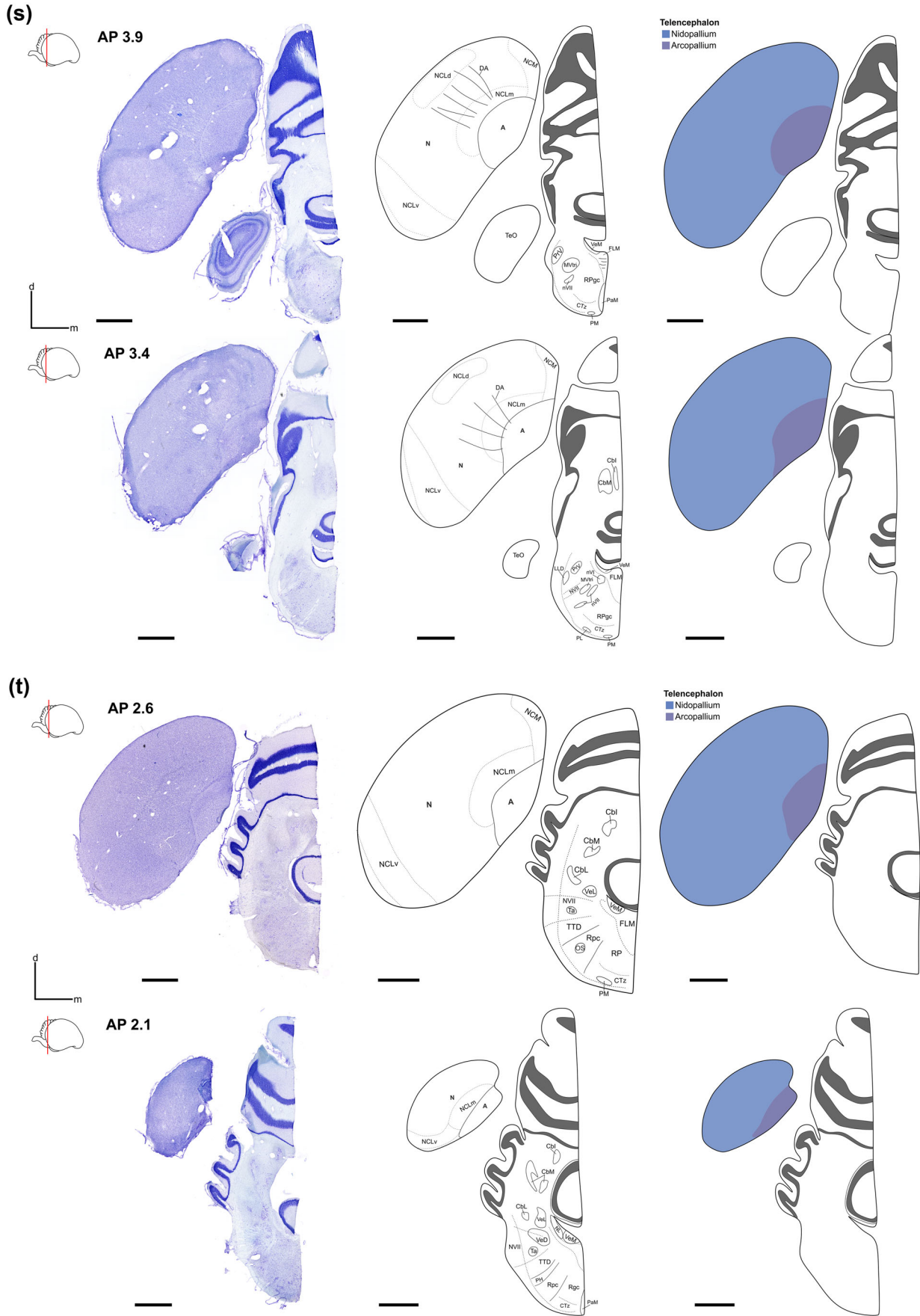


FIGURE 3 Continued

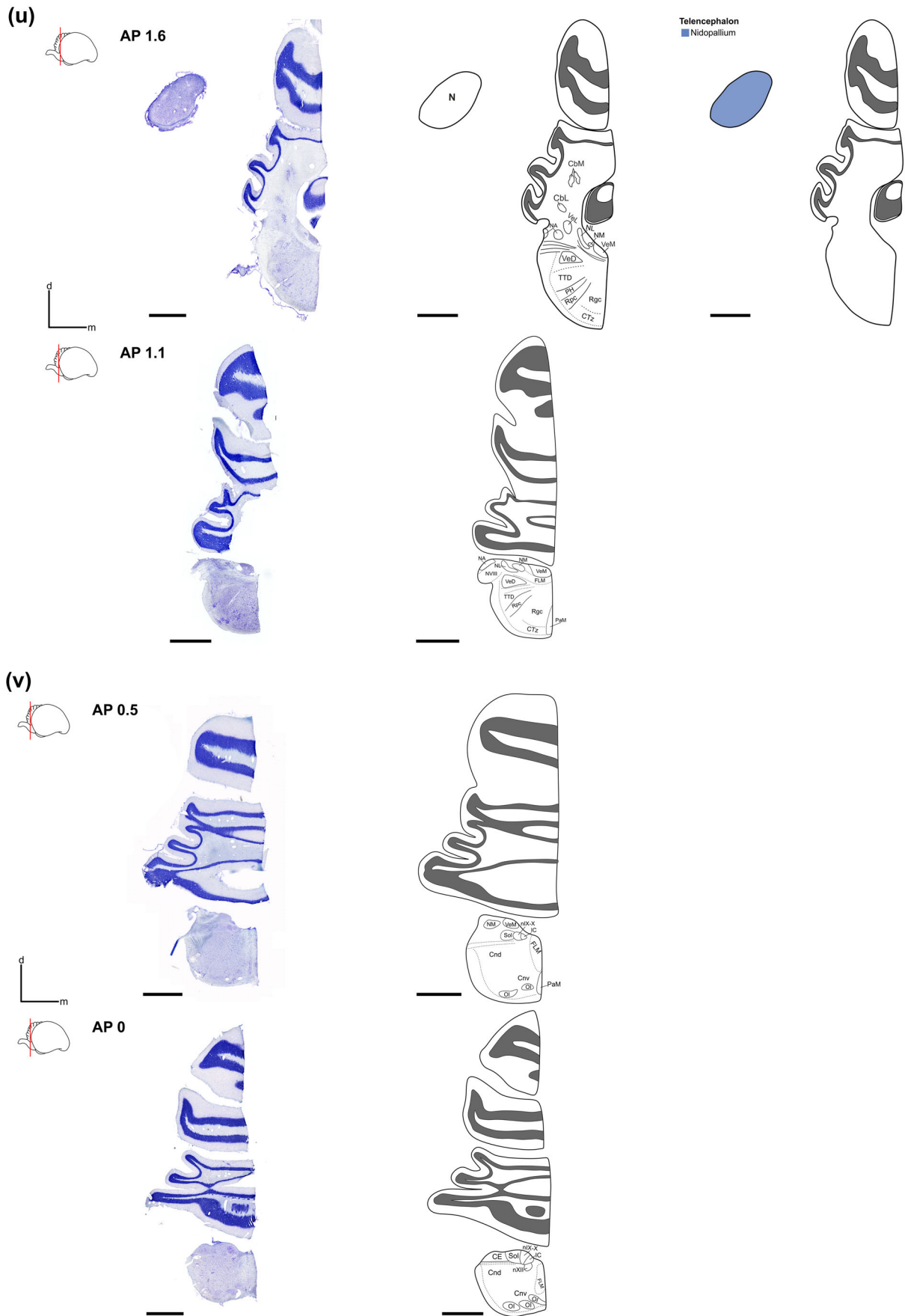


FIGURE 3 Continued

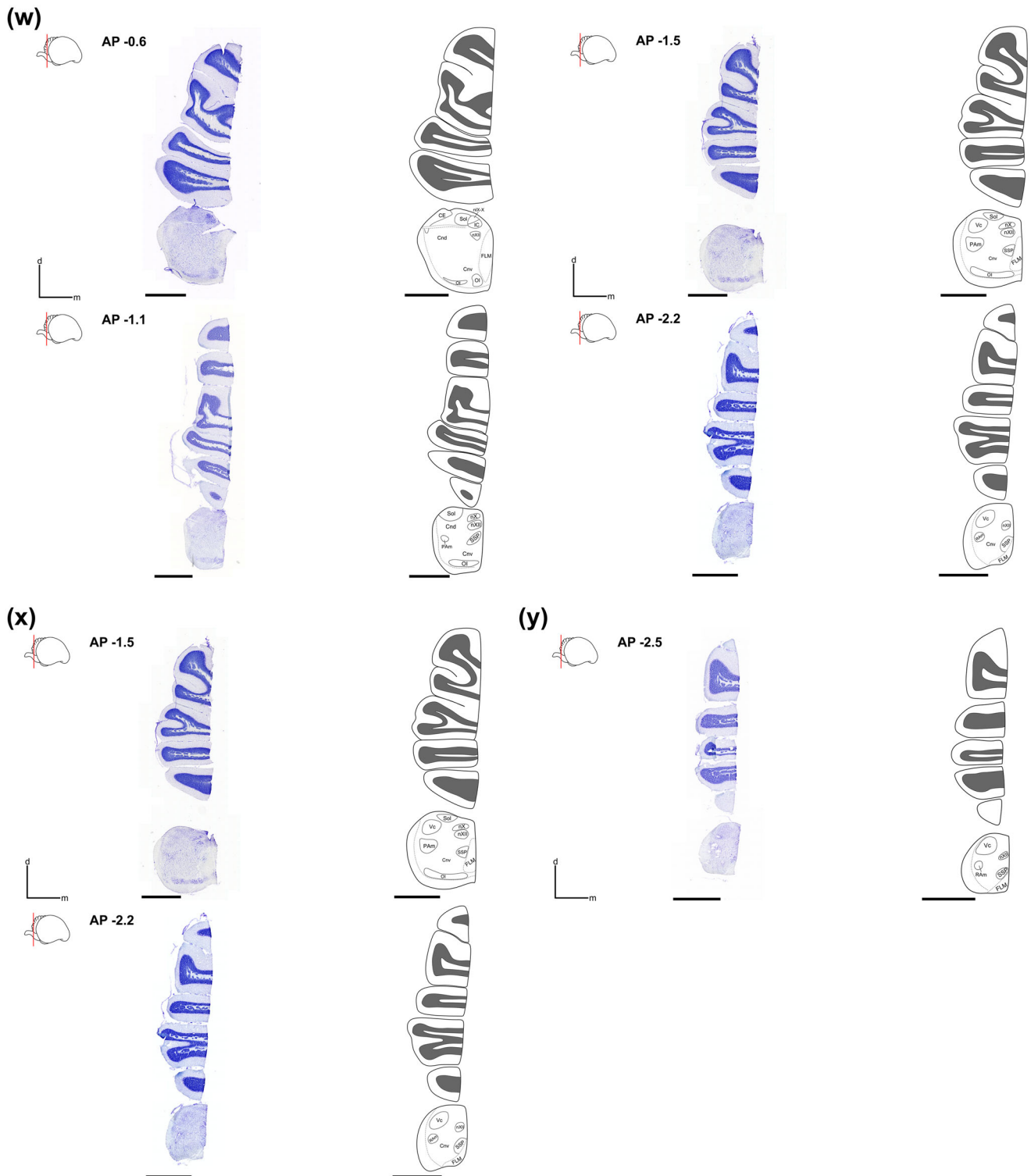


FIGURE 3 Continued

AP expansion elongates toward the medial NC. NCLd can mainly be characterized by a dense TH⁺ fiber mesh. Baskets are also visible, but it is more difficult to define them since the fibers mask the baskets. Moreover, NCLd can be localized by visualization of the dorsal arcopallial tract (DA; von Eugen et al., 2020), a reciprocal fiber tract between

the NCL and the intermediate arcopallium (AI; Kröner & Güntürkün, 1999; Figure 7b).

Apart from the NCL, a further subfield of the NC could be demarcated, the caudomedial nidopallium (NCM; Figure 3). The NCM is considered part of the auditory forebrain (Maney & Pinaud, 2011;

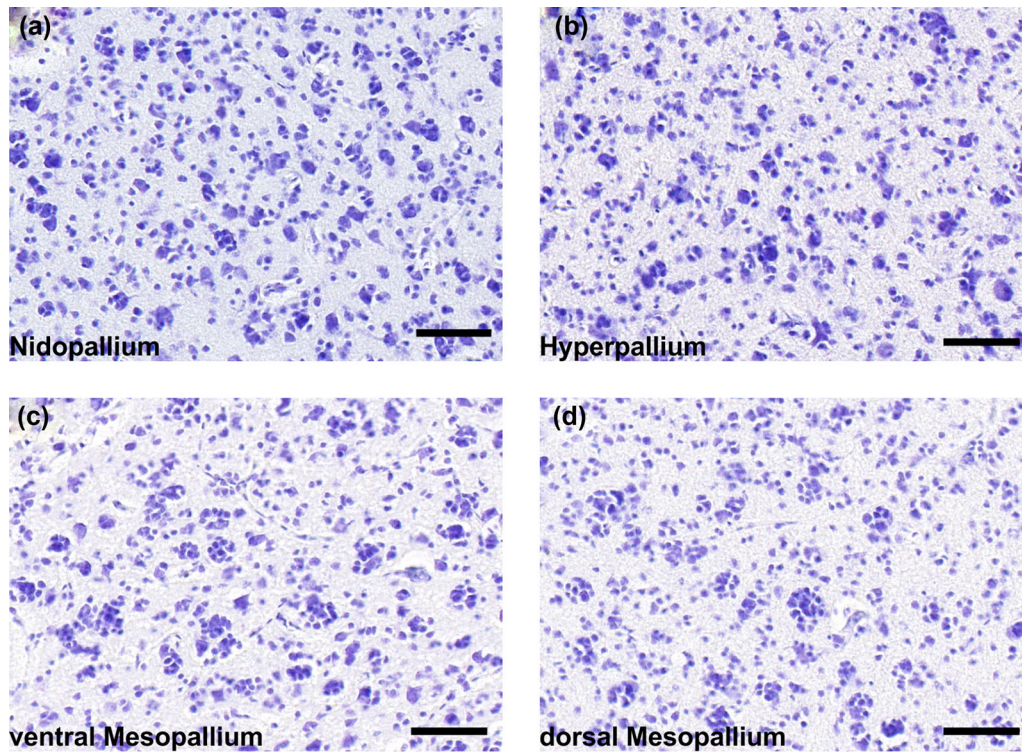


FIGURE 4 Characteristic clustering patterns of the cells in the different pallial subdomains visualized by Nissl staining. The arcopallium is not included since no uniform clustering characteristics could be found. Scale bars = 50 μm




FIGURE 5 3D reconstruction (NeuroLucida Software, MBF Bioscience) of the nidopallium (a,b), the mesopallium (c,d), the hyperpallium (e,f), the hippocampus (g,h), and the arcopallium and the striatum (i,k) to visualize the expansion of the different pallial subdomains throughout the cerebral crow's brain. The medial view of a domain is offered on the left, while the lateral view is offered on the right in one row

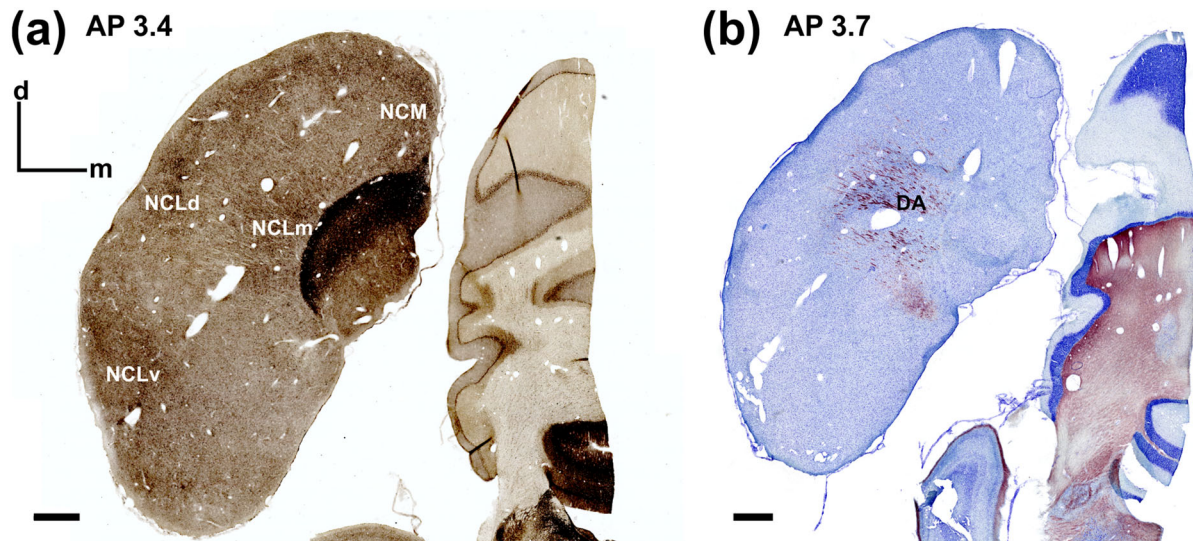


FIGURE 6 Subfields of the nidopallium caudolaterale (NCL; medial NCL, dorsal NCL (NCLd), ventral NCL, NCM) visualized in slides stained against TH (a). The subfields were identified based on TH+ fiber and basket characteristics. Moreover, slides stained against myelin show DA, which indicates the position of NCLd (b). Scale bars = 1000 μm . Abbreviations can be found in the abbreviation list

Mello & Clayton, 1994). In the crow, it is situated in the same AP range as the NCL; however, it appears in the medial nidopallium (Figure 6a). Compared to the NCL subfields, NCM shows a high TH+ fiber density and several baskets.

3.2 | Mesopallium

The mesopallium can be found from AP 9 to 23.3 and is situated dorsal to the nidopallium. To dorsal, the mesopallium borders the lateral ventricle and the hyperpallium (Figures 1, 3, and 5c,d). In high-resolution Nissl-stained slides, the mesopallium shows cells that cluster together in groups between 1 and 12 (Figure 4c,d). Moreover, the mesopallium can be divided into dorsal (MD) and ventral (MV) parts. In coronal sections, the MV can first be detected at AP 9 in the ventrolateral telencephalon, which grows medial while going rostrally until the MV sits dorsal to the N. From AP 13.3, the MD appears ventral to the H and dorsal to the MV. The two mesopallial regions are separated by the lamina mesopallium intermediate, while the lamina mesopallium dorsalis (LMD) separates the hyperpallium from the MD. In a 3D reconstruction, it appears as if the whole mesopallium is spread on top of the nidopallium (Figure 5c,d).

3.3 | Arcopallium

The arcopallium is the smallest pallial subarea compared to the meso-, nido- and hyperpallium. In the carrion crow, it reaches from AP 2.0 to 8.7 and is located in the caudoventral telencephalon (Figures 1 and 3). As in all songbirds, the arcopallium is located caudal to the striatum. The arcopallium can be separated from the striatum through the LPS, whereas LAD separates the arcopallium from the dorsolateral nidopallium (Figure 8). Unlike the nido-, meso- and hyperpallium, a reg-

ular cellular organization that fits the whole extent of the arcopallium is absent. Instead, five subareas of the arcopallium that were previously described in the zebra finch can also be identified in the crow (Mello et al., 2019). Mello et al. (2019) identified more than these five subareas based on molecular characteristics we did not apply in the current study. Nevertheless, we found subareas based on Nissl-stained slides and, for some subareas, were able to verify our assessment in anti-TH-stained slides. In the following, we will describe the arcopallium and its subdivisions in more detail.

In its posterior extent, the medial arcopallium (AM) shows darkly stained cells that cluster together in groups of five to 12 cells (Figure 8a). Lateral to this clustered region, a small triangular-shaped area can be observed; the cells in this area do not cluster together, appear lightly stained, and smaller, compared to the surrounding arcopallial tissue. We identify this area as the caudal part of the posterior arcopallium (APc) as shown by Mello et al. (2019) based on Zebra finch Expression Brain Atlas (ZEBra; www.zebrafinchatlas.org, RRID:SCR_012988).

Ventrolateral to these two areas (i.e., the APc and the densely packed area), the cells appear bigger and more loosely packed tissue (Figure 8a). We consider this area to match the AI as described in Mello et al. (2019). Further anteriorly, the densely packed area and APc disappear and are replaced by the AI region. In the dorsal arcopallial region, a stripe of cells appears to follow the bow of the LAD (Figure 8b). Moreover, this area is TH positive, as we find darkly stained fibers in anti-TH-stained slices. We identified this region as the dorsal arcopallium (AD) based on comparison with previous findings (Mello et al., 2019). Also, at this AP level, unstained fibers can be identified that pass between the arcopallium and the nidopallium and are most likely part of the DA (Figure 8b, arrows). More anteriorly, the robust nucleus of the arcopallium can be identified (RA). In addition, further subregions apart from the AI and AD can be found at this AP level. In the ventrolateral arcopallium, the anterior arcopallium (AA), a region

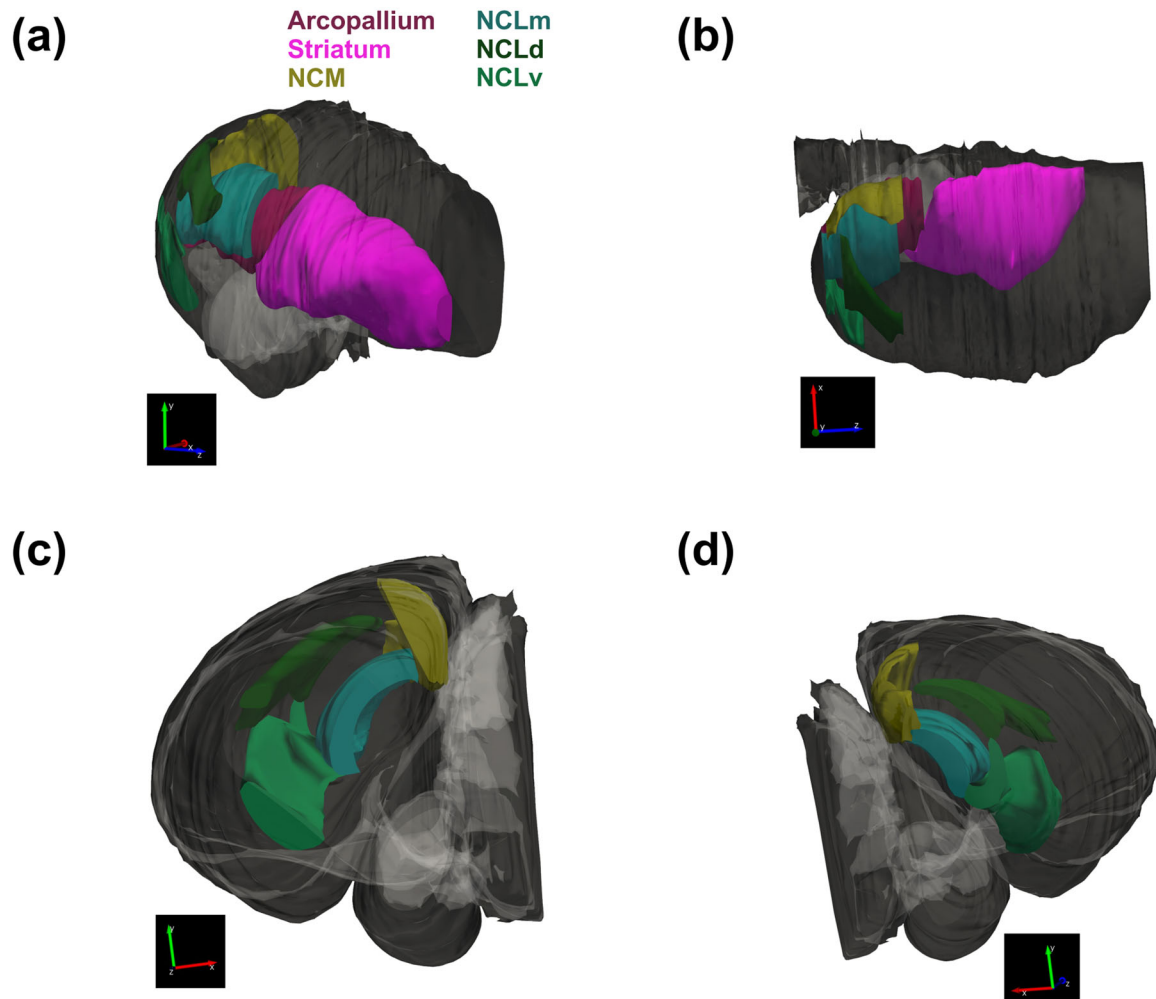


FIGURE 7 3D reconstruction of the expansion of the NCL subfields in the carrion crow in a from side view (a), dorsal view (b), rostral view (c), and caudal view (d). The reconstruction shows nicely that the NCL expands through the whole caudal nidopallium until the striatum starts and how the NCL wraps dorsally around the arcopallium

characterized by more densely packed cells, appears (Figure 8c). The cells form a stripe that follows the ventral border of the telencephalon. AA is laterally limited by the tractus fronto arcopallialis (FA), whereas the occipito-mesencephalic tract (OM) delineates the dorsal border (Figure 8d–f). The so-called AM can be delineated medial to the RA. Throughout the OM, it is divisible in a ventral and a dorsal part. The medial ventral arcopallium (AMV) can be first distinguished at the same rostrocaudal level as RA (AP 4.1) and appears as an elongated band of large, darkly stained cells (Figure 8c,d). The ventral and medial AMV is limited by the telencephalon border itself, while dorsally, the fiber tracts of the OM provide the borders of this subregion. Lateral AMV borders AA (Figure 8d,e). The dorsal part of the AM (AMD) is cornered medially by the medial border of the telencephalon, dorsally by the LAD, and ventrally by fiber tracts of the OM. Compared to the neighboring subregion AI, AMD shows smaller and more densely packed cells (Figure 8e,f). The AA region enlarges further anteriorly in its dorsal extent and additionally occupies a trapezoid-shaped area lateral to the OM fiber bundles (Figure 8e). Additionally, AMD enlarges laterally to occupy the area where RA tapers off (Figure 8d,e). At AP 7.1, the striatum starts lateral to the arcopallium (Figure 8e). The domains are

separated from each other by the LPS. On this level, the AMV shows in its most medial corner some small, densely packed and darkly stained cells, while in the rest of the AMV, the cells still show a more loosely packed arrangement (Figure 8e,f). Further anteriorly, the AMV shows smaller and smaller cells that appear densely packed until this characteristic comprises the whole area identified as the AMV (Figure 8f). Moreover, the area of the arcopallium narrows, and the OM fiber tracts occupy more space; therefore, AI also becomes narrower (Figure 8e,d). In the most rostral parts of the arcopallium, the AI area and the AA area disappear, and thus AMD and AMV cover most of the arcopallial region (Figure 8f).

3.4 | Hyperpallium

The hyperpallium can be found adjacent to the hippocampus, most dorsal in the crow's telencephalon, and reaches from AP 10.0 until the most rostral tip of the telencephalon around AP 24 (Figure 3). LMD separates the hyperpallium from the mesopallium, while to the medial, APH and dorsolateral corticoid area (CDL) can be distinguished based

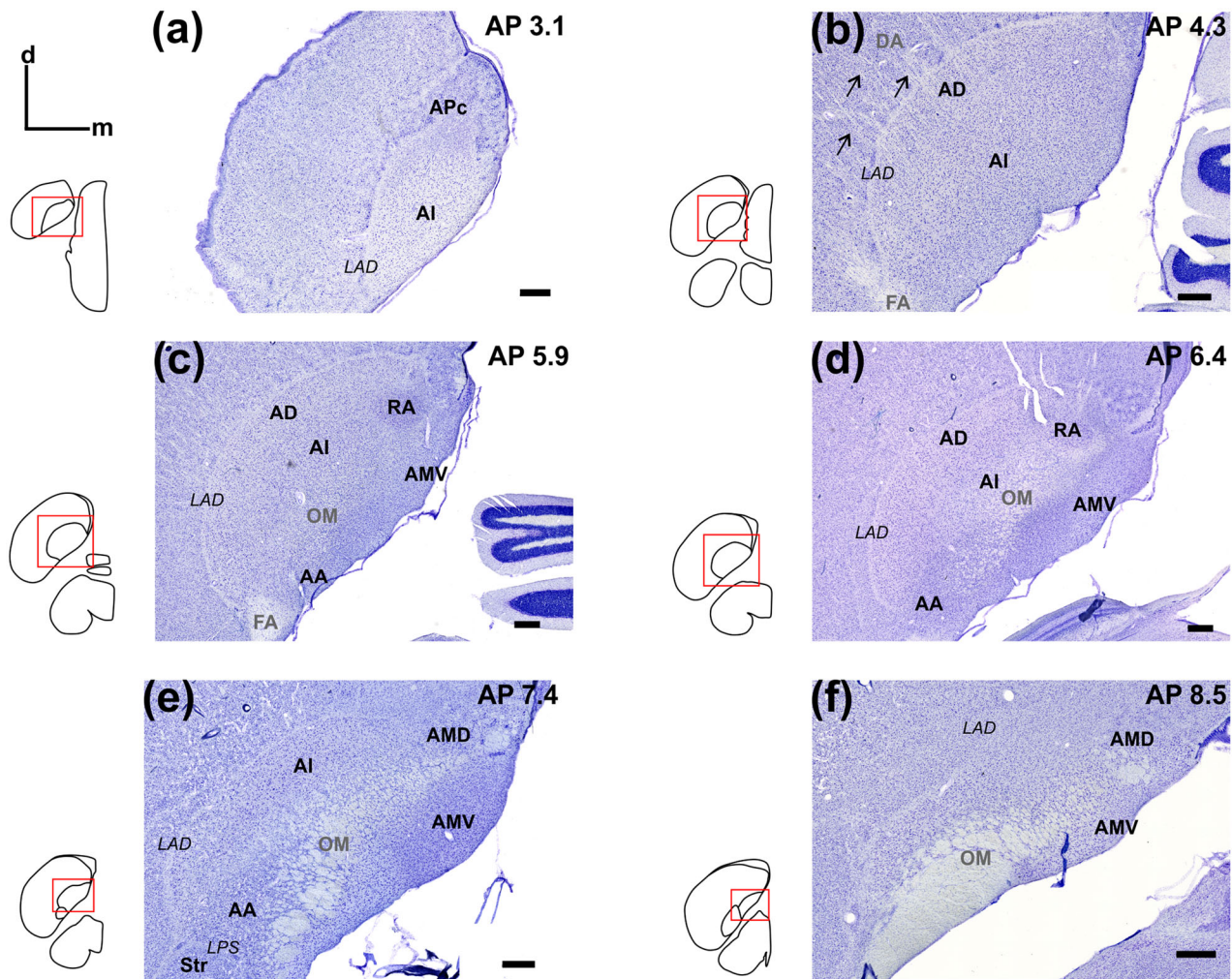


FIGURE 8 Subfields of the arcopallium visualized in Nissl-stained coronal sections from caudal to rostral (a–f). Coordinates indicate the location of the slides on the AP-axis. The insets give an overview of the location of the arcopallium in the telencephalon and relative to the other subdomains. Arrows in (b) point to dorsal arcopallial (DA). Scale bars = 500 μ m. Abbreviations can be found in the abbreviation list

on the cell clustering characteristics. We find the same cell clustering characteristics in the hyperpallium as in the nidopallium; thus, at high resolution, we find clusters of one to six cells (Figure 4a,b). In 3D reconstructions, it can be seen that the hippocampus and the hyperpallium form the roof of the crow's telencephalon. It appears as if both structures, especially the hyperpallium, were laid on top of the ventricle and the mesopallium (Figure 5c–h). We did not find any conspicuous features, such as layering or subdomains, in the hyperpallium based on our four staining techniques but were able to locate the core of the CDL (CDLco). We could locate it lateral to the CDL based on its cellular anatomy. Differing from the hyperpallium, CDLco is characterized by large cells that do not cluster together and are loosely packed. It is oval-shaped and can be found from AP 14.3 to 15.8 (Figure 3m,n).

3.5 | Hippocampal complex

In the avian brain, the term “hippocampal formation” summarizes the hippocampus and the parahippocampal area (APH; Atoji & Wild, 2006). In the carrion crow, the hippocampal formation is located above the

lateral ventricle. It shows its largest extent most medially. In its lateral extent, it tapers off caudally and disappears (Figure 5g,h). The hippocampal formation can first be found at AP 4.6 in coronal slides and reaches rostral until AP 20.7 (Figure 3). We are able to identify four subareas of the hippocampal formation and describe the lateral corticoid complex adjacent to the hippocampal formation. We, therefore, refer to the hippocampal complex to summarize both formations. We describe these subareas based on Nissl-stained sections in coronal slices, similar to Sen et al. (2019). Our identification of the crow's hippocampal subareas is based on comparisons with studies on the zebra finch (Lovell et al., 2020; Montagnese et al., 1996).

From caudal to rostral, the hippocampal formation is characterized by the APH at its most posterior extent; APH shows large cells without clustering (Figure 9a). Several subregions can be outlined further laterally. In the dorsal bend of the hippocampal complex, the crescent field (CF) appears. It appears as a region with small, densely packed cells that are surrounded by a ring of cell rare space (Figure 9b–f). Additionally, the medial hippocampus (HCm) can be localized at the most medial border of the hippocampal tissue as a stripe of densely

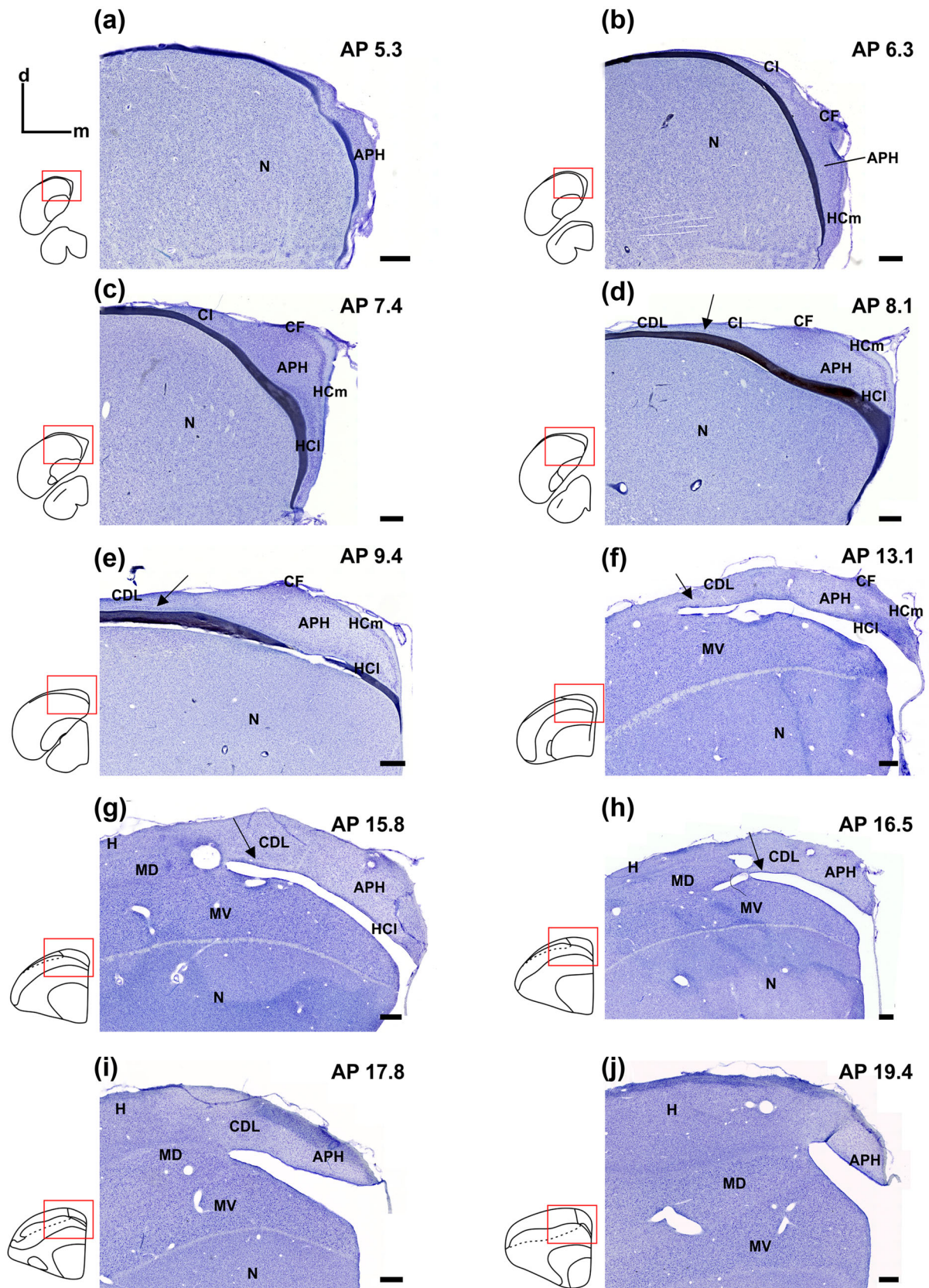


FIGURE 9 Subfields of the hippocampal complex covering the hippocampal formation and the lateral corticoid complex visualized in Nissl-stained coronal sections from caudal to rostral (a–j). Coordinates indicate the location of the slides on the AP-axis. The insets give an overview of the location of the hippocampal formation in the telencephalon relative to the other subdomains. Arrows in (d–h) point to the periventricular region. Scale bars = 500 μm. Abbreviations can be found in the abbreviation list

packed cells rendering it darker, compared to the surrounding tissue (Figure 9b–f). HCm starts at the ventro-medial tip and reaches the dorsal until it meets CF (Figure 9b–f). Bordering APH and CF laterally, the intermediate corticoid area (CI) can be found. It appears as an oval-shaped nucleus. CI appears lighter when compared to the surrounding tissue and can be traced back to a lower cell density (Figure 9b–d). Further rostrally, the lateral hippocampus (HCl) can be found lateral to HCm and together with it forms a V-shaped area. Similar to HCm, HCl appears as a slim stripe of densely packed cells, albeit not as darkly stained as in HCm (Figure 9c–g). Ventral to CI, we find the periventricular area, a stripe of large, sparsely packed cells that pulls laterally and is also visible ventral to CDL (Figure 9d–h, black arrow). Toward the anterior, the steep V-shaped area, consisting of HCm and HCl, retraces and flattens while simultaneously relocating dorsally (Figure 9c–e). Additionally, CI tapers off and cannot be found anymore (Figure 9e). CDL and the periventricular region taper off laterally until they meet the hyperpallium (H) approximately at the lateral corner of the lateral ventricle (Figure 9f–j). Further anteriorly, most of the subregions begin to disappear; around AP 13.2, CF cannot be discerned any longer, and APH replaces this region (Figure 9g), while HCm is no longer discernible at 13.4 (Figure 9f) and HCl at AP 16.0 (Figure 9g). From this point on, the hippocampal complex consists of APH and CDL until AP 18.5. Similar to the most caudal parts, the most anterior part of the hippocampus is characterized by the APH until it tapers off and disappears around AP 19.7 (Figure 9j).

3.6 | Striatum

The striatum can be found in the ventral telencephalon from AP 7.4 to 19.5 (Figure 3). Dorsally, it borders the nidopallium, while caudally, the arcopallium can be found (Figures 1, 3, and 5i,j). Both pallial subdomains are separated from the striatum by LPS. Rostral, the entopallium can be found lateral to the striatum (Figure 3). The striatum is clearly visible based on Nissl staining. Additionally, and differing from the pallial subdomains, we find high TH-positive levels over the whole striatal area. Moreover, this staining technique offers the opportunity to locate area X, an important song nucleus, in the rostral striatum (Figure 3) (for a detailed description of this song nucleus and the song system in the crow, see Kersten et al., 2021). Across the extent of the striatum, several large fiber tracts can be seen. Caudally, the striatum appears at the lateral tip of the arcopallium and, going rostrally, replaces it (Figure 3). At this point, the FA can be found lateral to the striatum, while the OM tract forms the ventral limit of the striatum and the telencephalon itself (Figure 3). OM tapers off around AP 9.8, and afterward, the tractus thalamo frontalis et frontalis-thalamicus medialis (TFM) that originates from the thalamus reaches in (Figure 3). This also marks the point where the telencephalon connects to the thalamus. Going further rostrally, TFM is joined by the fasciculus prosencephala lateralis (Figure 3). Both fiber tracts seem to be directed toward the globus pallidus (GP), which can be found in the lateral striatum from AP 10.0 to 13.9 (Figure 3). Apart from the area X and GP, another nucleus, the nucleus striae terminalis, can be found in the ventromedial striatum from AP 8.6 to AP 13.7 (Figure 3).

3.7 | Diencephalon/thalamus

The crow's thalamus resembles that of a typical songbird. Apart from the hypothalamus, the nucleus rotundus and the pretectal nucleus, larger thalamic nuclei can be seen. Among those, the medial part of the dorsolateral nucleus of the anterior thalamus plays a role in the song system. The auditory thalamic nucleus ovoidalis (Ov) and nucleus uvaeformis (Uva), which also play a role in song learning, are visible (Figure 3). Detailed descriptions of the thalamic nuclei that play a role in song learning and production can be found in our previous neuroanatomical study (Kersten et al., 2021).

3.8 | Midbrain

The main dorsal part of the midbrain is characterized by the tectum opticum (TeO) in the crow, which can be found from AP 3.0 to 11.4 (Figure 3). From AP 5.0 on, the TeO is continuous with the brainstem. Most prominently, we found the nucleus intercollicularis (ICo), nucleus mesencephalicuslateralis (MLd), dorsomedial part of the intercollicular nucleus (DM), nucleus isthmi pars magnocellularis, nucleus isthmi pars parvocellularis (Ipc) and nucleus semilunaris in the midbrain (SLu). With the help of TH staining, we were also able to identify the substantia nigra pars compacta (SNc) and the ventral tegmental area from AP 6.0 to 7.6 based on their strong TH-positivity in the midbrain (Figure 3).

3.9 | Brainstem (met- and myelencephalon)

We identified several brainstem nuclei in the crow's brain, of which most could be identified using Nissl-stained sections (Figure 3). However, when identifying the locus coeruleus (LoC, AP 4.2 to 5.4), TH staining was advantageous since this nucleus shows strong TH positivity. We identified nuclei of the lateral lemniscus (LLD, lateral lemniscus dorsal part; LLV, lateral lemniscus ventral part), nuclei of the trigeminal nerve (MVtri, motor trigeminal nucleus; PrV, principal trigeminal nucleus; Vc, caudal trigeminal nucleus) and the vestibular nuclei (VeM, nucleus vestibularis medialis, VeD, nucleus vestibularis descendens, VeL, nucleus vestibularis lateralis). Moreover, we found auditory brain nuclei, such as the nucleus olivary superior, nucleus magnocellularis (NM), nucleus angularis (NA), and nucleus laminaris (NL). In the most caudal sections of the crow's brain, we were able to identify the nuclei parambiguus and retroambiguus (RAm). As in other animal species, the medulla oblongata appears quite diffuse in the crow. However, with the help of the aforementioned brain atlases, we identified some of the most important brainstem nuclei (Figure 3).

4 | DISCUSSION

We present an anatomical mapping of the carrion crow's brain, in particular the pallial organization. Based on previous work on other crow species as well as on neuroanatomical data from the zebra finch and pigeon (Izawa & Watanabe, 2007; Karten & Hodos, 1968; Krützfeldt et al., 2010a, 2010b; Lovell et al., 2020; Mello et al., 2019;

Montagnese et al., 1996; Nixdorf-Bergweiler & Bischoff, 2007; Reinke & Wild, 1998; Sen et al., 2019; Wild, 1993, 1997a, 2010), we located several brain nuclei in the striatum, diencephalon, mesencephalon, and brainstem (met- and myelencephalon). Overall, we find a highly conserved organization of the crow's brainstem, midbrain, and thalamic nuclei. Despite the considerable brain size differences across species, the overall anatomy and Nissl characteristics are transferable to the crow brain. Concerning the brainstem anatomy, the pigeon atlas (Karten & Hodos, 1968) offered a good template. When studying the forebrain, the zebra finch atlas offered a more suitable option with respect to, for example, the different organization of the striatum and the arcopallium in songbird and nonsongbird brains (Mello et al., 2019; von Eugen et al., 2020). This global and stereotactic overview will promote further anatomical and physiological research in this bird species and in corvids in general.

4.1 | Nidopallium

We tracked the rostrocaudal extent of the nidopallium and described its main histological characteristics. We found the same cell clustering patterns that were described by Jarvis et al. (2013) in the zebra finch, and we were able to locate several distinct nuclei and functionally relevant subareas in the nidopallium. Overall, the neuroanatomical organization of the carrion crow hardly differs, compared to other songbirds, such as zebra finches or other corvid species such as the jungle crow.

Songbirds (and parrots) are known to have larger brains with an enlarged nidopallial area, compared to other avian orders (Iwaniuk & Hurd, 2005). Corvid songbirds even show larger nidopallial areas and brains than noncorvid songbirds (Mehlhorn et al., 2010). Moreover, there is evidence that the brain of corvids is a scaled-up version of the songbird brain since they also have higher neuronal numbers, a potential reason for the sophisticated cognitive behavior in birds of the corvid species (Olkowicz et al., 2016).

In general, the nidopallium together with the mesopallium processes sensory and cognitive information (Ulinsky, 1983; reviewed in Nomura & Izawa, 2017). In songbirds, such as the zebra finch and the crow, the nidopallium also harbors important song nuclei such as lateral part of magnocellular nucleus of the anterior nidopallium (MAN; IMAN or HVC, which are part of the anterior forebrain pathway important for song learning (IMAN, HVC), and the song motor pathway, which is important for singing (HVC; Nottebohm et al., 1982; Wild, 1997a; in crows discussed in Kersten et al., 2021; Wang et al., 2009). Moreover, we find the mentioned primary sensory territories (visual: entopallium, trigeminal: nucleus basorostralis pallii (BAS), auditory: field L) and the nidopallial song nuclei (Figure 3; Kersten et al., 2021).

Recently, a histological study shed some light on the location and trajectory of the NCL in carrion crows and several other bird species based on immunohistochemical staining of the dopaminergic innervation of the forebrain (von Eugen et al., 2020). The authors found some striking differences between songbirds (carrion crows and zebra finches) and birds of other orders in terms of the NCL organization (pigeons and chicken). They reported evidence pointing to at least

three different subareas of the avian NCL and proposed a fourth one in passerines. In our study, we also applied staining against TH, the rate-limiting enzyme for catecholamine synthesis (Smeets & Reiner, 1994), to visualize dopaminergic innervations of the pallial subdomains in the carrion crows. We were able to replicate the results of von Eugen et al. (2020) and could delineate the same subdomains (NCM, NCLm, NCLv, NCLd). The overall locations and TH characteristics were the same in our slides, albeit not all reported details were visible in our study. Moreover, tracing the exact borders of NCLv and NCLd in every section was sometimes challenging in the current investigation. Differences in tissue fixation and immunohistochemical protocols between von Eugen et al.'s (2020) study and our study could change the appearance of TH immunoreactivity across studies. In von Eugen et al.'s (2020) study, crows were shot by hunters and immersion fixed requiring heat-induced epitope retrieval (Jiao et al., 1999), whereas in our study, the crows were perfused to provide maximum tissue quality. Irrespective of these differences, we found all the core regions of the NCL subregions and reported the corresponding AP coordinates.

In addition to TH characteristics, the DA tract found passing between the arcopallium and NCLd offered a good indication of the location of NCLd: the DA tract could be easily visualized using our gold-chloride staining against myelin that we previously used to investigate the song system in the carrion crow (Kersten et al., 2021; Schmued, 1990). In zebra finches, this fiber connection is part of a multimodal network in the context of song learning between the IMAN, dNCL, and Av (Paterson & Bottjer, 2017). We delineated and tracked the song system in carrion crows in our previous study (Kersten et al., 2021). Since corvids can very flexibly use their vocalizations (Bluff et al., 2010; Brecht et al., 2019; Enggist-Dueblin & Pfister, 2002), it would be interesting to see the extent of the multimodal network incorporating song circuitry and NCL in carrion crows.

The NCL is considered the avian functional equivalent of the mammalian PFC (Divac and Mogensen, 1985; Güntürkün, 2005; Güntürkün and Bugnyar, 2016). In crows, the NCL has been shown to play an important role in cognitive control functions, a group of processes that direct, maintain, and manipulate information according to immediate task demands. NCL neurons respond to incoming sensory information (Veit et al., 2014; Wagener & Nieder, 2017) and signal the conscious perception of sensory stimuli (Nieder et al., 2020). NCL neurons classify sensory stimuli into behaviorally meaningful categories, such as numbers of items (Ditz & Nieder, 2015, 2016b, 2020; Ditz et al., 2022; Kirschhock et al., 2021). Importantly, many NCL neurons temporarily maintain and manipulate information in working memory after the stimulus disappears (Hahn et al., 2021; Rinnert et al., 2019; Veit et al., 2014), and they encode learned associations between arbitrary stimuli across temporal gaps (Moll & Nieder, 2015; Veit et al., 2015). NCL neurons also predict the instantaneous switching between abstract rules, such as "choose same" versus "choose different," in their neuronal responses (Veit & Nieder, 2013). Closing the perception-action cycle, NCL neurons finally play a role in preparing and executing motor behavior (Rinnert et al., 2019; Veit et al., 2017). In sum, to fulfill its role as a central executive, the corvid NCL encodes sensory and cognitive variables during working memory but also participates in the translation of cognitive signals to motor behaviors.

4.2 | Mesopallium

We were able to track and locate the mesopallium in the carrion crow's brain mostly based on Nissl-stained brain slices. During the mapping of the mesopallium and the other pallial subdomains, we successfully used the zebra finch atlas and the jungle crow atlas to identify different pallial areas (Izawa & Watanabe, 2007; Karten et al., 2013; Lovell et al., 2020). Overall, we did not find differences between the mentioned atlases and our results, despite the actual brain size differences.

Recently, the previously termed hyperpallium densocellulare (HD) was reevaluated since it shows more mesopallial characteristics than hyperpallial characteristics. Apart from molecular arguments, the previously termed HD also shows cell clustering characteristics that do not match the hyperpallium but rather the mesopallium (Gedman et al., 2021; Jarvis et al., 2013). In our investigation, we found the same cell cluster characteristics as in finches; however, in the absence of any genetic markers in our study, we cannot make strong statements concerning the former HD region. Nevertheless, based on the same cell clustering characteristics in the crow brain and because the change in nomenclature was accepted in the ZEBRA (Lovell et al., 2020), we adopt this new terminology for the crow pallium.

The mesopallium is reciprocally connected to trigeminal, visual and auditory primary sensory territories of the pallium, namely, the trigeminal BAS, the visual entopallium (E) and the auditory field L. The mesopallium is highly interconnected and processes sensory information in the avian brain (reviewed in Nomura & Izawa, 2017). Specifically, in parrots and songbirds, the mesopallium together with the nidopallium and striatopallidal proportions is much larger, compared to other bird groups (Iwaniuk & Hurd, 2005). Moreover, New Caledonian crows seem to have a larger mesopallium that has been discussed in the realm of enhanced sensory-motor skills in these tool-using crows (Mehlhorn et al., 2010).

Despite its intense connectivity patterns suggesting an integrative role, the functions of the mesopallium remain largely obscure. A connectivity analysis suggested the mesopallium mediale as part of a major associative network (Shanahan et al., 2013) that integrates input from all sensory streams and has reciprocal connections with the NCL (Atoji & Wild, 2012; Kröner & Güntürkün, 1999). Traditionally, the mesopallium is associated with imprinting in precocious birds (Lorenz, 1935). Lesioning or chemically blocking the intermediate and medial part of the mesopallium results in failed imprinting (Gabriel, 2004; Horn, 1998). In songbirds, the mesopallium is also part of the song system circuitry. The nucleus avalanche (Av) situated in the caudal mesopallium has been suggested in the formation of singing-related memories in the zebra finch (Keller & Hahnloser, 2009; Mandelblat-Cerf et al., 2014).

4.3 | Arcopallium

In this study, we were able to locate five subareas in the carrion crow's arcopallium based on Nissl-stained sections. We based our investigation of the arcopallium on previously published data from another songbird, the zebra finch. The subregions of the arcopallium are sometimes difficult to delineate, and only recently was a system-

atic investigation of the zebra finch arcopallium published (Mello et al., 2019). Using traditional Nissl staining and modern *in situ* hybridization analysis for autosomal-expressed genetic transcripts, the authors were able to delineate 20 subregions (Mello et al., 2019). We located the main subregions of the arcopallium in Nissl-stained sections in crows. The overall organization of the zebra finch arcopallium and the crows' arcopallium seem to be identical. Moreover, we also located RA, a nucleus of the song motor pathway (for a detailed description of RA and the song system in the carrion crow, see Kersten et al., 2021). We follow the recommendations of Mello and colleagues and renamed the area that was termed nucleus taenia amygdalae in the jungle crow to AMV in our carrion crows.

The arcopallium is a heterogeneous region in the avian pallium. In nonoscine birds, like chicken and pigeons, the arcopallium is located lateral to the striatum, while in oscine songbirds, like zebra finches or crows, the arcopallium is located caudo-medial to the striatum. Moreover, the arcopallium also underwent a rotation in songbirds; therefore, the AP axis in songbirds corresponds to the ML axis in nonoscines (Mello et al., 2019; von Eugen et al., 2020). Consequently, it is not clear which subareas in the songbird arcopallium correspond to subareas identified in nonoscines like pigeons and chickens (Mello et al., 2019). In general, the arcopallium seems to represent a major output structure through which sensory and motor pathways can be modulated and through which different behaviors can be expressed (Mello et al., 2019). In barn owls, inactivation of the arcopallium disrupts auditory spatial working memory (Knudsen & Knudsen, 1996). In finches, it processes vocal and other motor-related information (Yuan & Bottjer, 2020).

The arcopallium is the source of the OM, a large descending fiber tract (Shanahan et al., 2013; Zeier & Karten, 1971). In nonoscines, the arcopallium has been divided into the sensorimotor zone and viscerolimbic zone (Zeier & Karten, 1971). The viscerolimbic zone includes the nucleus taeniae and the posterior arcopallium, which some researchers think are part of the avian amygdala (e.g., Herold et al., 2018; Kröner & Güntürkün, 1999; Reiner et al., 2004). As reported for several avian groups, neurons from the nidopallium project both directly and indirectly to specific arcopallial areas for auditory and trigeminal pathways (Bottjer et al., 2000; Dubbeldam, 1998; Dubbeldam & Visser, 1987; Kröner & Güntürkün, 1999; Paterson and Bottjer, 2017).

4.4 | Hyperpallium

We were able to localize the hyperpallium itself but could not find any distinct layering, at least not with our applied staining techniques. A recent study has shown that the hyperpallial domain is topographically organized and shows a column-like neuronal circuitry (Stacho et al., 2020). While a distinct layering of the hyperpallium could be observed, layering was unclear and very thin in the pigeon hyperpallium, a finding reminiscent of our findings in the carrion crow. As discussed previously, we also renamed the HD to MD based on cell clustering patterns that match previous findings in the zebra finch (Jarvis et al., 2013), and we adopted the current nomenclature of ZEBRA. Thus,

the previously termed hyperpallium apicale (HA) does not need the term “apicale,” so we simply termed it hyperpallium (H). Overall, we do not find any differences between the carrion crow and the zebra finch or any other neuroanatomical data available for other corvid species (Izawa & Watanabe, 2007; Karten et al., 2013; Sen et al., 2019).

Traditionally, the hyperpallium in birds can be differentiated into three pseudolayers, the HA, the intermediate nucleus interstitialis hyperpallii apical (IHA) and the HD (now classified as MD (Jarvis et al., 2013; Nixdorf & Bischof, 1982). The hyperpallium or “Wulst” functionally consists of a smaller somatosensory region that can be found rostrally and a larger visual region that can be found caudally (Atoji & Wild, 2019; Martin Wild, 1987; Wild, 1992, 1997b). The rostral somatosensory HD projects to the rostral HA within the Wulst and to the limbic system outside of the Wulst. (Atoji & Wild, 2019; Atoji et al., 2018). However, the rostral HD also sends some output to the medial striatum, a connection that could not be found in the caudal HD (Atoji & Wild, 2019; Atoji et al., 2018). The rostral HA in turn sends projections to the lower brainstem and the cervical spinal cord (Wild, 1992), while additional studies in finches also revealed connections between the rostral HA and the song system (Wild & Williams, 1999, 2000). The caudal, visual hyperpallium is the telencephalic recipient of the visual thalamofugal pathway in birds; thus, it receives afferent connections from thalamic nuclei to the IHA. Here, the information is sent to HA and HD (MD). HA sends efferents to other telencephalic areas, such as the arcopallium and the nidopallium. Additionally, the tractus septomesencephalicus (TSM) originates in HA and carries information to thalamic nuclei and to the optical tectum (Güntürkün et al., 1993; Miceli et al., 1987).

4.5 | Hippocampal complex

We were able to map the hippocampal complex, including the hippocampal formation (hippocampus and the APH) and the corticoid complex, in the carrion crow's brain. We defined four subareas in the carrion crow's hippocampal formation based on Nissl-stained sections and described the adjacent lateral corticoid complex. We based our investigation on an earlier study on zebra finches (Montagnese et al., 1996). In this study, the authors were able to track five subareas in the hippocampal formation: the medial and HCl, the APH, the central field of the APH, and the CF. Except for the central field of the APH, all subareas were visible by Nissl staining. We were unable to locate the fifth subarea, the central field of the APH, since it is not visible in Nissl staining but is characterized by the dendritic characteristics of the neurons, which were visualized using Golgi staining (Montagnese et al., 1996). Therefore, our results are in line with histological data collected in the zebra finch and an immunohistological study done in house crows (Montagnese et al., 1996; Sen et al., 2019).

In pigeons, a study combining Nissl staining and tract-tracing found seven subdivisions in the hippocampal formation (Atoji & Wild, 2004). When comparing the subdivisions found in the zebra finch and the crow with those of the pigeon, the V-shaped area including its medial and lateral layer seems to be comparable to HCm and HCl based on the Nissl characteristics. However, we could not find the horizontal layer

of the ventral thin wall that is present in the pigeon because the tissue does not expand far enough ventrally in the crow. Additionally, CF in our results potentially resembles some parts of magnocellular and parvocellular regions. We could also not find the parahippocampal sulcus, preventing us from defining the dorsolateral and dorsomedial (DM) portion of the hippocampal in the carrion crow. In summary, we think the zebra finch hippocampal complex resembles the carrion crow's hippocampal complex (Montagnese et al., 1996).

Functionally, the hippocampus is associated with spatial cognition. Its involvement in spatial navigation could be shown in pigeons (Bingman et al., 1984, 1988) and in zebra finches (Bailey et al., 2009). Moreover, the hippocampus is especially important for food storing birds and even undergoes seasonal changes during both the breeding seasons and in different seasons of the year (Bingman & MacDougall-Shackleton, 2017; Sherry & Hoshoooley, 2010; Sherry & MacDougall-Shackleton, 2015). For example, some corvid species, like jays, store food for the winter and recover their food by remembering where they have hidden their caches (Dally et al., 2006). Lesion studies confirmed that the hippocampus is crucial for the retrieval of food and therefore seems to play a crucial role in memory for the spatial location of the cached food (Sherry et al., 1989). Recently, head direction cells and place cells, both important for orienting in space, were recorded in birds (Ben-Yishay et al., 2021; Payne et al., 2021). Nonspatial information, however, does not seem to be represented in the crow hippocampus (Ditz et al., 2018). Since corvids are also food-storing songbirds, it would be interesting to see whether the crow's hippocampus also contains place cells.

5 | CONCLUSIONS

Over the last decades, corvid songbirds became renowned for their sophisticated cognitive behaviors, which in turn prompted interest in understanding the neural foundations that give rise to corvid cognition. To better understand corvid brain anatomy, we introduce the brain atlas of the carrion crow (*C. corone*), a typical and widespread crow species, as a representative atlas for corvid songbirds. This will allow us to identify corvid neuroanatomical specializations that may be responsible for advanced cognition in this songbird family vis-à-vis noncorvid songbirds and other orders of birds. In addition, knowledge about the location and extent of brain areas and nuclei is a prerequisite for targeted physiological investigations that began in the carrion crow a few years ago and are expected to intensify in the future, potentially also in other corvid species. In the future, the connections between brain areas have to be deciphered, potentially by applying tract-tracing methods in the same species. Even though comparatively little is known about corvid neuroanatomy, we envision crows as a welcome and paradigmatic species in avian cognitive neuroscience.

ACKNOWLEDGMENTS

We are most grateful to Harvey Karten and Agnies Brzozowska-Prechtel (University of California at San Diego, USA) for sharing the immunohistochemistry protocol, the Giemsa counterstain protocol,

and the Gallyas Myelin protocol. We are also grateful to Henry Evrard (Center for Integrative Neuroscience, University Tübingen) and his work group for sharing the Zeiss Axio Scanner and helpful comments and discussions regarding the staining techniques.

CONFLICT OF INTEREST

The authors declare that they have no conflict of interest.

DATA AVAILABILITY STATEMENT

The data that support the findings of this study are available from the corresponding author upon reasonable request.

PEER REVIEW

The peer review history for this article is available at <https://publons.com/publon/10.1002/cne.25392>.

REFERENCES

- Atoji, Y., Sonjoy, S., & Wild, J. M. (2018). Differential projections of the densocellular and intermediate parts of the hyperpallium in the pigeon (*Columba livia*) Yasuro. *Journal of Comparative Neurology*, 526, 146–156.
- Atoji, Y., & Wild, J. M. (2004). Fiber connections of the hippocampal formation and septum and subdivisions of the hippocampal formation in the pigeon as revealed by tract tracing and kainic acid lesions. *Journal of Comparative Neurology*, 475, 426–461.
- Atoji, Y., & Wild, J. M. (2006). Anatomy of the avian hippocampal formation. *Reviews in Neuroscience*, 17, 3–15.
- Atoji, Y., & Wild, J. M. (2019). Projections of the densocellular part of the hyperpallium in the rostral Wulst of pigeons (*Columba livia*). *Brain Research*, 1711, 130–139.
- Atoji, Y., & Wild, J. M. (2012). Afferent and efferent projections of the mesopallium in the pigeon (*Columba livia*). *Journal of Comparative Neurology*, 520(4), 717–741. <https://doi.org/10.1002/cne.22763>. PMID:21935938
- Bingman, V. P., & MacDougall-Shackleton, S. A. (2017). The avian hippocampus and the hypothetical maps used by navigating migratory birds (with some reflection on compasses and migratory restlessness). *Journal of Comparative Physiology A*, 203(6-7), 465–474. <https://doi.org/10.1007/s00359-017-1161-0>. PMID: 28299428
- Bailey, D. J., Wade, J., & Saldanha, C. J. (2009). Hippocampal lesions impair spatial memory performance, but not song—A developmental study of independent memory systems in the Zebra Finch. *Developmental Neurobiology*, 69, 491–504.
- Ben-Yishay, E., Krivoruchko, K., Ron, S., Ulanovsky, N., Derdikman, D., & Gutfreund, Y. (2021). Directional tuning in the hippocampal formation of birds. *Current Biology*, 31, 2592–2602.
- Bingman, V. P., Bagnoli, P., Ioalé, P., & Casini, G. (1984). Homing behavior of pigeons after telencephalic ablations. *Brain, Behavior and Evolution*, 24, 94–108.
- Bingman, V. P., Ioalé, P., Casini, G., & Bagnoli, P. (1988). Unimpaired acquisition of spatial reference memory but impaired homing performance in hippocampal-ablated pigeons. *Behavioural Brain Research*, 27, 179–187.
- Bluff, L. A., Kacelnik, A., & Rutz, C. (2010). Vocal culture in New Caledonian crows, *Corvus moneduloides*. *Biological Journal of the Linnean Society*, 101, 767–776.
- Boeckle, M., & Bugnyar, T. (2012). Long-term memory for affiliates in ravens. *Current Biology*, 22, 801–806.
- Bottjer, S. W., Brady, J. D., & Cribbs, B. (2000). Connections of a motor cortical region in zebra finches: Relation to pathways for vocal learning. *Journal of Comparative Neurology*, 420, 244–260.
- Brecht, K. F., Hage, S. R., Gavrilov, N., & Nieder, A. (2019). Volitional control of vocalizations in corvid songbirds. *PLoS Biology*, 17, 1–14.
- Burish, M. J., Kueh, H. Y., & Wang, S. S. H. (2004). Brain architecture and social complexity in modern and ancient birds. *Brain, Behavior and Evolution*, 63, 107–124.
- Clayton, N., & Emery, N. (2005). Quick guide. Corvid cognition. *Current Biology*, 15, 80.
- Dally, J. M., Emery, N. J., & Clayton, N. S. (2006). Food-caching western scrub-jays keep track of who was watching when. *Science*, 312, 1662–1665.
- De Knijff, P. (2014). How carrion and hooded crows defeat Linnaeus's curse. *Science*, 344, 1345–1346.
- Ditz, H. M., Fechner, J., & Nieder, A. (2022). Cell-type specific pallial circuits shape categorical tuning responses in the crow telencephalon. *Communications Biology*, 5, 1–13.
- Ditz, H. M., Kupferman, J. K., & Nieder, A. (2018). Neurons in the hippocampus of crows lack responses to non-spatial abstract categories. *Frontiers in Systems Neuroscience*, 12, 1–10.
- Ditz, H. M., & Nieder, A. (2015). Neurons selective to the number of visual items in the corvid songbird endbrain. *Proceedings of the National Academy of Sciences of the United States of America*, 112, 7827–7832.
- Ditz, H. M., & Nieder, A. (2016a). Numerosity representations in crows obey the Weber-Fechner law. *Proceedings. Biological Sciences*, 283(1827), 20160083.
- Ditz, H. M., & Nieder, A. (2016b). Sensory and working memory representations of small and large numerosities in the crow endbrain. *Journal of Neuroscience*, 36, 12044–12052.
- Ditz, H. M., & Nieder, A. (2020). Format-dependent and format-independent representation of sequential and simultaneous numerosity in the crow endbrain. *Nature Communications*, 11, 1–10.
- Divac, I., & Mogensen, J. (1985). The prefrontal “cortex” in the pigeon catecholamine histofluorescence. *Neuroscience*, 15, 677–682.
- Dubbeldam, J. L. (1998). The sensory trigeminal system in birds: Input, organization and effects of peripheral damage. A review. *Archives of Physiology and Biochemistry*, 106, 338–345.
- Dubbeldam, J. L., & Visser, A. M. (1987). The organization of the nucleus basalis-neostriatum complex of the mallard (*Anas platyrhynchos* L.) and its connections with the archistriatum and the paleostriatum complex. *Neuroscience*, 21, 487–517.
- Enggist-Dueblin, P., & Pfister, U. (2002). Cultural transmission of vocalizations in ravens, *Corvus corax*. *Animal Behaviour*, 64, 831–841.
- Ericson, P. G. P., Jansén, A. -L., Johansson, U. S., & Ekman, J. (2005). Inter-generic relationships of the crows, jays, magpies and allied groups (Aves: Corvidae) based on nucleotide sequence data. *Journal of Avian Biology*, 36, 222–234.
- Gabriel, H. (2004). Paythways of the past: The imprinting memory. *Nature Reviews Neuroscience*, 5, 108–120.
- Gedman, G., Haase, B., Durieux, G., Biegler, M. T., Fedrigo, O., & Jarvis, E. D. (2021). As above, so below: Whole transcriptome profiling demonstrates strong molecular similarities between avian dorsal and ventral pallial subdivisions. *Journal of Comparative Neurology*, 529, 3222–3246.
- Güntürkün, O. (2005). The avian ‘prefrontal cortex’ and cognition. *Current Opinion in Neurobiology*, 15, 686–693.
- Güntürkün, O., & Bugnyar, T. (2016). Cognition without Cortex. *Trends in Cognitive Sciences*, 20, 291–303.
- Güntürkün, O., Miceli, D., & Watanabe, M. (1993). Anatomy of the avian thalamofugal pathway. In H. P. Zeigler, & H. -J. Bischof (Eds.), *Vision, brain, and behavior in birds* (pp 115–135). The MIT Press.
- Hahn, L. A., Balakhonov, D., Fongaro, E., Nieder, A., & Rose, J. (2021). Working memory capacity of crows and monkeys arises from similar neuronal computations. *Elife*, 10, 1–21.
- Haring, E., Däubli, B., Pinsker, W., Kryukov, A., & Gamauf, A. (2012). Genetic divergences and intraspecific variation in corvids of the genus *Corvus* (Aves: Passeriformes: Corvidae)—A first survey based on museum

- specimens. *Journal of Zoological Systematics and Evolutionary Research*, 50, 230–246.
- Herold, C., Paulitschek, C., Palomero-Gallagher, N., Güntürkün, O., & Zilles, K. (2018). Transmitter receptors reveal segregation of the arcopallium/amygdala complex in pigeons (*Columba livia*). *Journal of Comparative Neurology*, 526, 439–466.
- Holtz, P. (1939). Dopadecarboxylase. *Naturwissenschaften*, 27, 724–725.
- Horn, G. (1998). Visual imprinting and the neural mechanisms of recognition memory. *Trends in Neurosciences*, 21, 300–305.
- Iwaniuk, A. N., & Hurd, P. L. (2005). The evolution of cerebrotypes in birds. *Brain, Behavior and Evolution*, 65, 215–230.
- Izawa, E. -I., & Watanabe, S. (2007). A stereotaxic atlas of the brain of the jungle crow (*Corvus macrorhynchos*). In S. Watanabe, M. A. Hofman, & K. G. Daigaku (Eds.), *Integration of comparative neuroanatomy and cognition*, (pp. 215–273.) Keio University Press.
- Jarvis, E. D., Yu, J., Rivas, M. V., Horita, H., Feenders, G., Whitney, O., Jarvis, S. C., Jarvis, E. R., Kubikova, L., Puck, A. E. P., Siang-Bakshi, C., Martin, S., McElroy, M., Hara, E., Howard, J., Pfenning, A., Mouritsen, H., Chen, C. C., & Wada, K. (2013). Global view of the functional molecular organization of the avian cerebrum: Mirror images and functional columns. *Journal of Comparative Neurology*, 521, 3614–3665.
- Jiao, Y., Sun, Z., Lee, T., Fusco, F. R., Kimble, T. D., Meade, C. A., Cuthbertson, S., & Reiner, A. (1999). A simple and sensitive antigen retrieval method for free-floating and slide-mounted tissue sections. *Journal of Neuroscience Methods*, 93, 149–162.
- Karten, H. J., & Hodos, W. (1967). A stereotaxic atlas of the brain of the pigeon (*Columba livia*) (Vol. 696). Johns Hopkins Press.
- Karten, H. J., Brzozowska-Precht, A., Lovell, P. V., Tang, D. D., Mello, C. V., Wang, H., & Mitra, P. P. (2013). Digital atlas of the zebra finch (*Taeniopygia guttata*) brain: A high-resolution photo atlas. *Journal of Comparative Neurology*, 521, 3702–3715.
- Karten, H. J., & Hodos, W. (1968). *A stereotaxic atlas of the brain of the pigeon (Columbia livia)*. Johns Hopkins Press.
- Keller, G. B., & Hahnloser, R. H. R. (2009). Neural processing of auditory feedback during vocal practice in a songbird. *Nature*, 457, 187–190.
- Kersten, Y., Friedrich-Müller, B., & Nieder, A. (2021). A histological study of the song system of the carrion crow (*Corvus corone*). *Journal of Comparative Neurology*, 529(10), 2576–2595.
- Kirschhock, M. E., Ditz, H. M., & Nieder, A. (2021). Behavioral and neuronal representation of numerosity zero in the crow. *Journal of Neuroscience*, 41, 4889–4896.
- Knudsen, E. I., & Knudsen, P. F. (1996). Disruption of auditory spatial working memory by inactivation of the forebrain archistriatum in barn owls. *Nature*, 383, 428–431.
- Kröner, S., & Güntürkün, O. (1999). Afferent and efferent connections of the caudolateral neostriatum in the pigeon (*Columba uvia*): A retro- and anterograde pathway tracing study. *Journal of Comparative Neurology*, 407, 228–260.
- Krützfeldt, N. O. E., Logerot, P., Fabiana Kubke, M., & Martin Wild, J. (2010a). Connections of the auditory brainstem in a songbird, *Taeniopygia guttata*. II. Projections of nucleus angularis and nucleus laminaris to the superior olive and lateral lemniscal nuclei. *Journal of Comparative Neurology*, 518, 2135–2148.
- Krützfeldt, N. O. E., Logerot, P., Kubke, M. F., & Wild, J. M. (2010b). Connections of the auditory brainstem in a songbird, *Taeniopygia guttata*. I. Projections of nucleus angularis and nucleus laminaris to the auditory torus. *Journal of Comparative Neurology*, 518, 2109–2134.
- Kryukov, A., Spiridonova, L., Nakamura, S., Haring, E., & Suzuki, H. (2012). Comparative phylogeography of two crow species: Jungle crow *Corvus macrorhynchos* and carrion crow *Corvus corone*. *Zoological Science*, 29, 484–492.
- Kuenzel, W. J., & Masson, M. (1988). A stereotaxic atlas of the brain of the chick (*Gallus domesticus*). Johns Hopkins University Press.
- Lorenz, K. (1935). Der Kumpan in der Umwelt des Vogels. *Journal für Ornithologie*, 83, 137–213.
- Lovell, P. V., Wirthlin, M., Kaser, T., Buckner, A. A., Carleton, J. B., Snider, B. R., McHugh, A. K., Tolpygo, A., Mitra, P. P., & Mello, C. V. (2020). ZEBra: Zebra finch Expression Brain Atlas—A resource for comparative molecular neuroanatomy and brain evolution studies. *Journal of Comparative Neurology*, 528, 2099–2131.
- Mandelblat-Cerf, Y., Las, L., Denisenko, N., & Fee, M. S. (2014). A role for descending auditory cortical projections in songbird vocal learning. *Elife*, 3, 1–23.
- Maney, D., & Pinaud, R. (2011). Estradiol-dependent modulation of auditory processing and selectivity in songbirds. *Frontiers in Neuroendocrinology*, 32, 287–302.
- Martin Wild, J. (1987). The avian somatosensory system: connections of regions of body representation in the forebrain of the pigeon. *Brain Research*, 412, 205–223.
- Mehlhorn, J., Hunt, G. R., Gray, R. D., Rehkämper, G., & Güntürkün, O. (2010). Tool-making new caledonian crows have large associative brain areas. *Brain, Behavior and Evolution*, 75, 63–70.
- Mello, C. V., & Clayton, D. F. (1994). Song-induced ZENK gene expression in auditory pathways of songbird brain and its relation to the song control system. *Journal of Neuroscience*, 14, 6652–6666.
- Mello, C. V., Kaser, T., Buckner, A. A., Wirthlin, M., & Lovell, P. V. (2019). Molecular architecture of the zebra finch arcopallium. *Journal of Comparative Neurology*, 527, 2512–2556.
- Miceli, D., Repérant, J., Villalobos, J., & Dionne, L. (1987). Extratelencephalic projections of the avian visual Wulst. A quantitative autoradiographic study in the pigeon *Columbia livia*. *Journal für Hirnforsch*, 28, 45–57.
- Moll, F. W., & Nieder, A. (2015). Cross-modal associative mnemonic signals in crow endbrain neurons. *Current Biology*, 25, 2196–2201.
- Montagnese, C. M., Krebs, J. R., & Meyer, G. (1996). The dorsomedial and dorsolateral forebrain of the zebra finch, *Taeniopygia guttata*: A Golgi study. *Cell and Tissue Research*, 283, 263–282.
- Nieder, A. (2017). Inside the corvid brain—probing the physiology of cognition in crows. *Current Opinion in Behavioral Sciences*, 16, 8–14.
- Nieder, A., Wagener, L., & Rinnert, P. (2020). A neural correlate of sensory consciousness in a corvid bird. *Science*, 369, 1626–1629.
- Nixdorf-Bergweiler, B., & Bischoff, H.-J. (2007). *A stereotaxic atlas of the brain of the zebra finch, Taeniopygia guttata, with special special emphasis on telencephalic visual and song system nuclei in transverse and sagittal sections*. National Library of Medicine, National Center for Biotechnology Information.
- Nixdorf, B. E., & Bischoff, H.-J. (1982). Afferent connections of the ectostriatum and visual Wulst in the zebra finch (*Taeniopygia guttata castanotis* Gould): An HRP study. *Brain Research*, 248, 9–17.
- Nomura, T., & Izawa, E. I. (2017). Avian brains: Insights from development, behaviors and evolution. *Development, Growth & Differentiation*, 59, 244–257.
- Nottebohm, F., Paton, J. A., & Kelley, D. B. (1982). Connections of vocal control nuclei in the canary telencephalon. *Journal of Comparative Neurology*, 207, 344–357.
- Olkowicz, S., Kocourek, M., Luèan, R. K., Porteš, M., Fitch, W. T., Herculano-Houzel, S., & Nemeč, P. (2016). Birds have primate-like numbers of neurons in the forebrain. *Proceedings of the National Academy of Sciences of the United States of America*, 113, 7255–7260.
- Parkin, D. T., Collinson, J. M., & Knox, A. (2003). The taxonomic status of the carrion and hooded crows. *British Birds*, 96, 274–290.
- Paterson, A. K., & Bottjer, S. W. (2017). Cortical inter-hemispheric circuits for multimodal vocal learning in songbirds. *Journal of Comparative Neurology*, 525, 3312–3340.
- Payne, H. L., Lynch, G. F., & Aronov, D. (2021). Neural representations of space in the hippocampus of a food-caching bird. *Science*, 373, 343–348.
- Poelstra, J. W., Vijay, N., Bossu, C. M., Lantz, H., Ryll, B., Müller, I., Baglione, V., Unneberg, P., Wikelski, M., Grabherr, M. G., & Wolf, J. B. W. (2014). The

- genomic landscape underlying phenotypic integrity in the face of gene flow in crows. *Science*, 344, 1410–1414.
- Puelles, L., Paxinos, G., Watson, C., Martinez, S., & Martinez-de-la-Torre, M. (2007). *The chick brain in stereotaxic coordinates: An atlas based on neuromeres*. Elsevier Science & Technology Books.
- Rehkämper, G., Frahm, H. D., & Zilles, K. (1991). Quantitative development of brain and brain structures in birds (galliformes and passeriformes) compared to that in mammals (insectivores and primates) (Part 2 of 2). *Brain, Behavior and Evolution*, 37, 135–143.
- Reiner, A., Perkel, D. J., Bruce, L. L., Butler, A. B., Csiilag, A., Kuenzel, W., Medina, L., Paxinos, G., Shimizu, T., Striedter, G., Wild, M., Ball, G. F., Durand, S., Güntürkün, O., Lee, D. W., Mello, C. V., Powers, A., White, S. A., Hough, G., & Kubikova, L. (2004). Revised nomenclature for avian telencephalon and some related brainstem nuclei. *Journal of Comparative Neurology*, 473, 377–414.
- Reinke, H., & Wild, J. M. (1998). Identification and connections of inspiratory premotor neurons in songbirds and budgerigar. *Journal of Comparative Neurology*, 391, 147–163.
- Rinnert, P., Kirschhock, M. E., & Nieder, A. (2019). Neuronal correlates of spatial working memory in the endbrain of crows. *Current Biology*, 29, 2616–2624.e4.
- Rinnert, P., & Nieder, A. (2021). Neural code of motor planning and execution during goal-directed movements in crows. *Journal of Neuroscience*, 41, 4060–4072.
- Sherry, D. F., & Hoshooey, J. S. (2010). Seasonal hippocampal plasticity in food storing birds. *Philosophical Transactions–Royal Society of London Series B Biological Sciences*, 365(1542), 933–943. <https://doi.org/10.1098/rstb.2009.0220>. PMID: 20156817; PMCID: PMC2830249
- Sherry, D. F., & MacDougall-Shackleton, S. A. (2015). Seasonal change in the avian hippocampus. *Frontiers in Neuroendocrinology*, 37, 158–67. <https://doi.org/10.1016/j.yfrne.2014.11.008>. PMID: 25497862
- Schmued, L. C. (1990). A rapid, sensitive histochemical stain for myelin in frozen brain sections. *Journal of Histochemistry and Cytochemistry*, 38, 717–720.
- Sen, S., Parishar, P., Pundir, A. S., Reiner, A., & Iyengar, S. (2019). The expression of tyrosine hydroxylase and DARPP-32 in the house crow (*Corvus splendens*) brain. *Journal of Comparative Neurology*, 527, 1801–1836.
- Shanahan, M., Bingman, V. P., Shimizu, T., Wild, M., & Güntürkün, O. (2013). Large-scale network organisation in the avian forebrain: A connectivity matrix and theoretical analysis. *Frontiers in Computational Neuroscience*, 7, 89.
- Sherry, D. F., Vaccarino, A. L., Buckenham, K., & Herz, R. S. (1989). The hippocampal complex of food-storing birds. *Brain, Behavior and Evolution*, 34, 308–317.
- Smeets, W. J., & Reiner, A. (1994). *Phylogeny and development of catecholamine systems in the CNS of vertebrates*. Cambridge University Press.
- Stacho, M., Herold, C., Rook, N., Wagner, H., Axer, M., Amunts, K., & Güntürkün, O. (2020). A cortex-like canonical circuit in the avian forebrain. *Science*, 369, 1–12.
- Stokes, T. M., Leonard, C. M., & Nottebohm, F. (1974). The telencephalon, diencephalon, and mesencephalon of the canary, serinus canaria, in stereotaxic coordinates. *Journal of Comparative Neurology*, 156, 337–374.
- Ströckens, F., Neves, K., Kirchem, S., Schwab, C., Herculano-Houzel, S., & Güntürkün, O. (2022). High associative neuron numbers could drive cognitive performance in corvid species. *Journal of Comparative Neurology*, 530(10), 1588–1605.
- Ulinsky, P. S. (1983). *Dorsal ventricular ridge: A treatise on forebrain organization in reptiles and birds*. Wiley Interscience.
- Van Tienhoven, A., & Juhasz, L. P. (1962). The chicken telencephalon, diencephalon and mesencephalon in stereotaxic coordinates. *Journal of Comparative Neurology*, 118, 185–197.
- Veit, L., Hartmann, K., & Nieder, A. (2014). Neuronal correlates of visual working memory in the corvid endbrain. *Journal of Neuroscience*, 34, 7778–7786.
- Veit, L., Hartmann, K., & Nieder, A. (2017). Spatially tuned neurons in corvid nidopallium caudolaterale signal target position during visual search. *Cerebral Cortex*, 27, 1103–1112.
- Veit, L., & Nieder, A. (2013). Abstract rule neurons in the endbrain support intelligent behaviour in corvid songbirds. *Nature Communications*, 4, 1–11.
- Veit, L., Pidpruzhnykova, G., & Nieder, A. (2015). Associative learning rapidly establishes neuronal representations of upcoming behavioral choices in crows. *Proceedings of the National Academy of Sciences of the United States of America*, 112, 15208–15213.
- von Eugen, K., Tabrik, S., Güntürkün, O., & Ströckens, F. (2020). A comparative analysis of the dopaminergic innervation of the executive caudal nidopallium in pigeon, chicken, zebra finch, and carrion crow. *Journal of Comparative Neurology*, 528(19), 2929–2955.
- Wagener, L., & Nieder, A. (2017). Encoding of global visual motion in the nidopallium caudolaterale of behaving crows. *European Journal of Neuroscience*, 45, 267–277.
- Waldmann, C., & Güntürkün, O. (1993). The dopaminergic innervation of the pigeon caudolateral forebrain: immunocytochemical evidence for a “prefrontal cortex” in birds? *Brain Research*, 600, 225–234.
- Wang, R., Sun, Y., Zhang, X., Zeng, S., Xie, W., Yu, Y., Zhang, X., & Zuo, M. (2009). Song control nuclei in male and female large-billed crows (*Corvus macrorhynchos*). *Zoological Science*, 26, 771–777.
- Weir, A. A. S., Chappell, J., & Kacelnik, A. (2002). Shaping of hooks in new Caledonian crows. *Science*, 297(5583), 981.
- Wild, J. M. (1992). Direct and indirect “cortico”-rubral and rubro-cerebellar cortical projections in the pigeon. *Journal of Comparative Neurology*, 326, 623–636.
- Wild, J. M. (1993). The avian nucleus retroambiguus for breathing, singing and calling. *Brain Research*, 606, 319–324.
- Wild, J. M. (1997a). Neural pathways for the control of birdsong production. *Journal of Neurobiology*, 33, 653–670.
- Wild, J. M. (1997b). The avian somatosensory system: The pathway from wing to Wulst in a passerine (*Chloris chloris*). *Brain Research*, 759, 122–134.
- Wild, J. M., & Williams, M. N. (1999). Rostral wulst of passerine birds: II. Intratelencephalic projections to nuclei associated with the auditory and song systems. *Journal of Comparative Neurology*, 413, 520–534.
- Wild, J. M., & Williams, M. N. (2000). Rostral Wulst in passerine birds. I. Origin, course, and terminations of an avian pyramidal tract. *Journal of Comparative Neurology*, 416, 429–450.
- Wild, J. M., Krützfeldt, N. O. E., & Fabiana Kubke, M. (2010). Connections of the auditory brainstem in a songbird, taeniopygia guttata. III. Projections of the superior olive and lateral lemniscal nuclei. *Journal of Comparative Neurology*, 518, 2149–2167.
- Wolf, J. B. W., Bayer, T., Haubold, B., Schilhabel, M., Rosenstiel, P., & Tautz, D. (2010). Nucleotide divergence vs. gene expression differentiation: Comparative transcriptome sequencing in natural isolates from the carrion crow and its hybrid zone with the hooded crow. *Molecular Ecology*, 19, 162–175.
- Yuan, R. C., & Bottjer, S. W. (2020). Sensory and motor systems multidimensional tuning in motor cortical neurons during active behavior. *eNeuro*, 7, 1–24.
- Zeier, H., & Karten, H. J. (1971). The archistriatum of the Pigeon: Organization of the afferent and efferent connections. *Brain Research*, 31, 313–326.

How to cite this article: Kersten, Y., Friedrich-Müller, B., & Nieder, A. (2022). A brain atlas of the carrion crow (*Corvus corone*). *Journal of Comparative Neurology*, 1–28. <https://doi.org/10.1002/cne.25392>